

Pantoea agglomerans: a mysterious bacterium of evil and good. Part III. Deleterious effects: infections of humans, animals and plants

Jacek Dutkiewicz¹, Barbara Mackiewicz², Marta Kinga Lemieszek³, Marcin Golec¹, Janusz Milanowski²

¹ Department of Biological Health Hazards and Parasitology, Institute of Rural Health, Lublin, Poland

² Department of Pneumonology, Oncology and Allergology, Medical University, Lublin, Poland

³ Department of Medical Biology, Institute of Rural Health, Lublin, Poland

Dutkiewicz J, Mackiewicz B, Lemieszek MK, Golec M, Milanowski J. *Pantoea agglomerans*: a mysterious bacterium of evil and good. Part III. Deleterious effects: infections of humans, animals and plants. Ann Agric Environ Med. 2016; 23(2): 197–205. doi: 10.5604/12321966.1203878

Abstract

Pantoea agglomerans, a bacterium associated with plants, is not an obligate infectious agent in humans. However, it could be a cause of opportunistic human infections, mostly by wound infection with plant material, or as a hospital-acquired infection, mostly in immunocompromised individuals. Wound infection with *P. agglomerans* usually follow piercing or laceration of skin with a plant thorn, wooden splinter or other plant material and subsequent inoculation of the plant-residing bacteria, mostly during performing of agricultural occupations and gardening, or children playing. Septic arthritis or synovitis appears as a common clinical outcome of exogenous infection with *P. agglomerans*, others include endophthalmitis, periostitis, endocarditis and osteomyelitis. Another major reason for clinical infection with *P. agglomerans* is exposure of hospitalized, often immunodeficient individuals to medical equipment or fluids contaminated with this bacterium. Epidemics of nosocomial septicemia with fatal cases have been described in several countries, both in adult and paediatric patients. In most cases, however, the clinical course of the hospital-acquired disease was mild and application of the proper antibiotic treatment led to full recovery. Compared to humans, there are only few reports on infectious diseases caused by *Pantoea agglomerans* in vertebrate animals. This species has been identified as a possible cause of equine abortion and placentitis and a haemorrhagic disease in dolphin fish (*Coryphaena hippurus*). *P. agglomerans* strains occur commonly, usually as symbionts, in insects and other arthropods. *Pantoea agglomerans* usually occurs in plants as an epi- or endophytic symbiont, often as mutualist. Nevertheless, this species has also been identified as a cause of diseases in a range of cultivable plants, such as cotton, sweet onion, rice, maize, sorghum, bamboo, walnut, an ornamental plant called Chinese taro (*Alocasia cucullata*), and a grass called onion couch (*Arrhenatherum elatius*). Some plant-pathogenic strains of *P. agglomerans* are tumourigenic, inducing gall formation on table beet, an ornamental plant gypsophila (*Gypsophila paniculata*), wisteria, Douglas-fir and cranberry. Recently, a *Pantoea* species closely related to *P. agglomerans* has been identified as a cause of bacterial blight disease in the edible mushroom *Pleurotus eryngii* cultivated in China. The genetically governed determinants of plant pathogenicity in *Pantoea agglomerans* include such mechanisms as the hypersensitive response and pathogenicity (*hrp*) system, phytohormones, the quorum-sensing (QS) feedback system and type III secretion system (T3SS) injecting the effector proteins into the cytosol of a plant cell.

Key words

Pantoea agglomerans, infections, humans, vertebrate animals, arthropods, plant pathogen, genetic determinants

Causative agent of opportunistic infections in humans

Pantoea agglomerans is not an obligate infectious agent in humans. However, it could be a cause of the opportunistic (occasional) human infections, mostly in 2 situations: 1) wound infection with plant material, and 2) hospital-acquired infection. Cases which do not fall into these 2 categories are less numerous.

Wound infection with *P. agglomerans* could follow piercing or laceration of skin with a plant thorn, wooden splinter or other plant material, usually during performing of agricultural occupations [1, 2], during gardening [3, 4, 5, 6] or children playing [7, 8, 9, 10, 11, 12, 13], and subsequent inoculation of the plant-residing bacteria. Recently, Vaiman

et al. [14] found in a retrospective study that all 9 patients with 1–2 months of ineffective treatment of post-traumatic wounds showed the presence of foreign bodies of plant origin infected with *Pantoea agglomerans*. Removal of the foreign bodies led to rapid healing of the wounds in 2–3 days. Septic arthritis or synovitis appears as a common clinical outcome of exogenous infection with *P. agglomerans* (Figs. 1–2) [4, 5, 7, 9, 10, 11, 12, 13], others include endophthalmitis [3, 6, 15, 16], acute unilateral dacryocystitis, peculiar by the kind of eye contaminant – not a plant material but dog feces [17], corneal infiltrate in an agricultural worker after rice husk injury, caused by *Pantoea ananatis*, a species closely related to *P. agglomerans* [18], periostitis [8], endocarditis [19], osteomyelitis after injury with rose thorn [20] or after closed fracture [21], tibial osteitis after an open grade IIIB tibial shaft fracture [22], and a tumour-like muscle cyst of the thigh [2].

Exposure of hospitalized, often immunocompromised individuals, to medical equipment or fluids contaminated with

Address for correspondence: Prof. Jacek Dutkiewicz, Department of Biological Health Hazards and Parasitology, Institute of Rural Health, Jaczewskiego 2, 20-090 Lublin, Poland
E-mail: dutkiewicz.jacek@imw.lublin.pl

Received: 08 March 2016; accepted: 20 April 2016

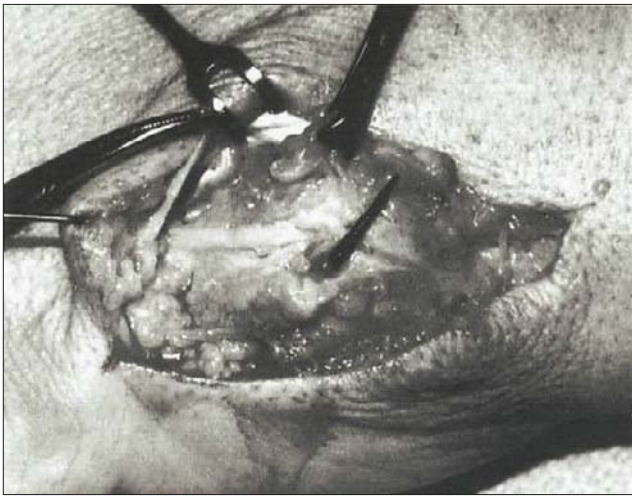


Figure 1. A case of plant thorn synovitis of the hand joint caused by *P. agglomerans* in an adult male. Photomicrograph is showing a large plant thorn spike and the surrounding synovial reaction. According to Oleniński et al. [4], with permission

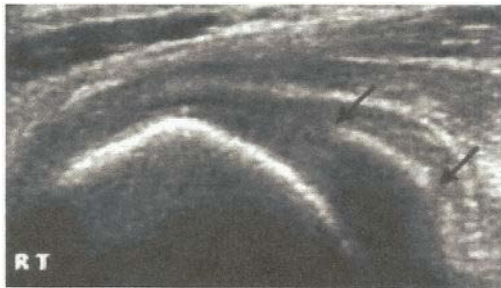

Figure 2. A case of the knee arthritis caused by *P. agglomerans* in a 14-year-old boy, following penetration by a palm tree thorn. Foreign body with approximate length of 8 mm (the palm thorn) is seen (between the black arrows) in the posterior lateral aspect of the knee. According to Kratz et al. [11], with permission

P. agglomerans [23, 24, 25, 26, 27, 28] is another major reason for clinical infections with this bacterium. The greatest nosocomial (hospital-borne) epidemic caused by *P. agglomerans* and other enterobacteria, which occurred in the USA between 1970–1971 and resulted in 378 cases of septicemia (of which 152 caused solely by *P. agglomerans*) with 13.4% mortality, was proved to have been spread by the factory-contaminated screw-caps of bottles with intravenous fluids [23]. Contamination of the screw-caps of the bottles containing the intravenous fluid with *P. agglomerans* and *Enterobacter cloacae* also caused the epidemic of nosocomial sepsis with 6.3% mortality among 63 Greek infants and children [24]. More recently, there was described in Malaysia an outbreak of septicemia with respiratory failure, with a very high mortality (87.5%) among neonates in an intensive care unit caused by parenteral nutrition solutions infected with *Pantoea* spp. [25, 29]. Bicudo et al. [30] described a nosocomial outbreak of *P. agglomerans* sepsis with gastrointestinal symptoms in 6 paediatric patients in Brazil, caused by contaminated transference tube used for intravenous rehydration. Boszczowski et al. [28], also in Brazil, reported an outbreak of *P. agglomerans* bacteraemia in 7 patients receiving haemodialysis or plasmapheresis, caused by contamination of an anticoagulant citrate-dextrose 46% solution produced by the hospital's compound pharmacy. Cruz et al. [31] described 53 paediatric cases of *Pantoea agglomerans* infections cultured from normally sterile sites

in patients seen at a children's hospital in Houston, USA, over 6 years. Isolates included 23 from the bloodstream, 14 from abscesses, 10 from joints/bones, 4 from the urinary tract, and 1 each from the peritoneum and the thorax. Infections were mostly polymicrobial, mortality equaled to 5.7%. *P. agglomerans* was most associated with penetrating trauma by vegetative material and catheter-related bacteraemia.

The other cases of hospital-acquired *P. agglomerans* infection with identified source of contamination include: pneumonia in a heart-lung transplant recipient following transplantation (Fig. 3) [26], a ventilator-associated pneumonia in a patient with chronic renal failure [32], septicemia after blood transfusion [27], septicemia in oncologic patients due to infected catheters [33], and endocarditis in a patient with mitral valve leaflet prolapse [34].

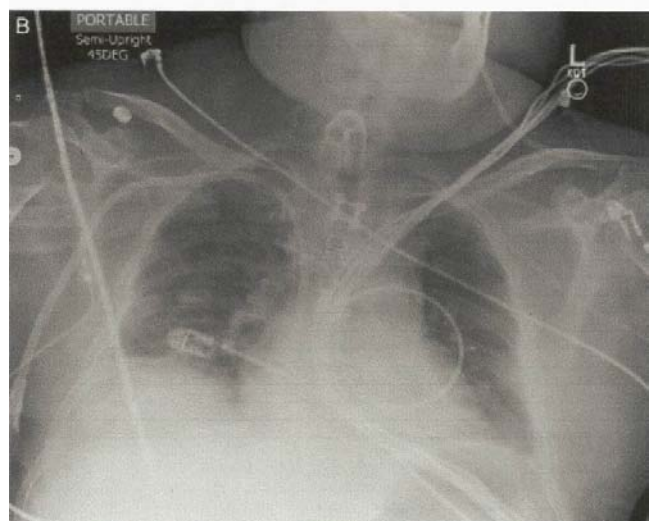
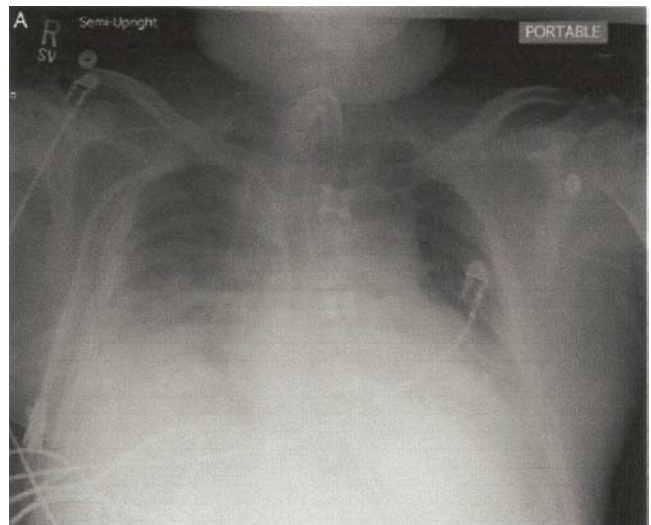

Figure 3. A case of pneumonia caused by *P. agglomerans* in a heart-lung transplant recipient. (A) Patient's chest radiograph shows bilateral lower lobe consolidation on the day of diagnostic bronchoscopy, and (B) interval improvement in bilateral lower lobe consolidation 10 days after initiation of appropriate antimicrobial therapy. According to Shubov et al. [26], with permission.

Some infections with *P. agglomerans* associated with the stay in hospital cannot be traced to any documented way of infection and are defined as 'endogenous', 'spontaneous' or 'sporadic' infections. They are presumably due to the decline

of patients' immunity caused by underlying disease and/or hospital procedures [35, 36, 37, 38]. Thus, Bergman et al. [35] reported 125 infections with *P. agglomerans* among 6,383 newborns hospitalized in an intensive care unit, of whom 3 developed 'sporadic' septicaemia and died. In contrast, Aly et al. [36] described 5 cases of 'sporadic' septicaemia in preterm neonates with favourable outcome due to a proper antibiotic therapy. Cases of such *P. agglomerans* septicaemias were described in a child with rotavirus gastroenteritis [39] and in an adult patient with colon cancer [40]. Cheng et al. [38] reported that at the large medical centre in Taiwan, the diagnosis of 'spontaneous' *P. agglomerans* bacteraemia could be established between the years 2000–2010 in 18 adult patients, and was significantly associated with gastroesophageal reflux disease and receipt of antacids.

Liberto et al. [41] reported an outbreak of *P. agglomerans* septicaemia among the adult oncologic patients of a teaching hospital with undetermined source of infection. In other adult patients, Wang and Fraser [42] isolated *P. agglomerans* from brain abscess that developed after infarction and hemisectomy, while Hischebeth et al. [43] identified *P. agglomerans* as a cause of an acute hip prosthetic joint infection. Seok et al. [44] described a case of bilateral endogenous endophthalmitis caused by *Pantoea agglomerans* in a patient who had interstitial lung disease and was treated with oral corticosteroids (Figs. 4–5), whereas Kletke et al. [45] reported unilateral endogenous endophthalmitis elicited by this bacterium in an otherwise healthy male. In another study, Flores Popoca et al. [46] demonstrated that *Pantoea*

agglomerans strains prevailed among bacteria isolated from the sputa of immunodeficient patients with different respiratory diseases, which indicates the potential role of this species as a possible secondary pathogen.

Pantoea agglomerans seems to be a relatively common cause of peritonitis in the adult patients with renal failure receiving peritoneal dialysis [37, 47, 48, 49, 50, 51]. In 2 cases the injury with a rose thorn was suspected as the cause of infection [47, 49], and in 1 case a contaminated catheter caused the disease [51]; in all the other cases the source of infection in the patients receiving dialysis remained obscure [37, 48, 50].

Naha et al. [52] reported an interesting case of septicaemia caused by *P. agglomerans* in an immunocompetent Indian farmer with no history of wounding. In spite of this, the authors postulate the occupational background of the disease and suggest that severe infections with *P. agglomerans* may become increasingly frequent in the agricultural populations. A similar case of infectious pneumonia caused by *P. agglomerans* in an otherwise healthy man has been described by Garcia-Pardo et al. [53]. In contrast, Al-Damluji et al. [54], who described earlier a lethal case of primary pneumonia caused by *P. agglomerans* in a carpenter (Fig. 6), did not presume any association of the disease with occupation. It must be underscored, however, that despite a large respiratory exposure to *P. agglomerans* in many agricultural occupations [55], the numbers of occupational infections with this bacterium are extremely low. Porter and Wray [56] presented another interesting case of *P. agglomerans* infection in an immunocompetent, young British farmer which appeared as spondylodiscitis, a condition not previously associated with this bacterium. Although also in this case an occupational background could be suspected, the authors presumed that the infection could be rather an unwanted complication of tetracycline therapy. Rodrigues et al. [57] and Fullerton et al. [58] described cases of liver abscesses caused by *P. agglomerans* (Fig. 7), the latter complicated by acute myositis leading to rhabdomyolysis and renal failure. In a study by Gonçalves et al. [59] *Pantoea agglomerans* has been identified as a permanent constituent of

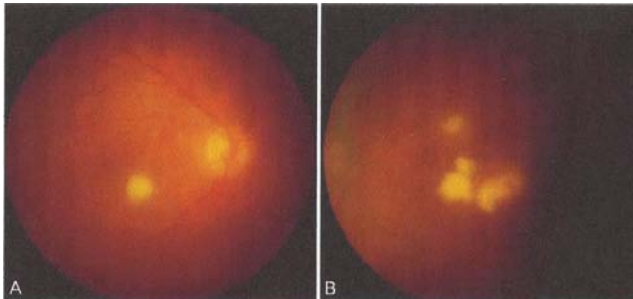


Figure 4. A case of bilateral endogenous endophthalmitis caused by *P. agglomerans* in a patient with interstitial lung disease. (A) Right eye – exudate is round, whitish-yellow, and slightly elevated towards the vitreous cavity. (B) Left eye – exudates are irregular, whitish-yellow, and slightly elevated towards the vitreous cavity. According to Seok et al. [44]

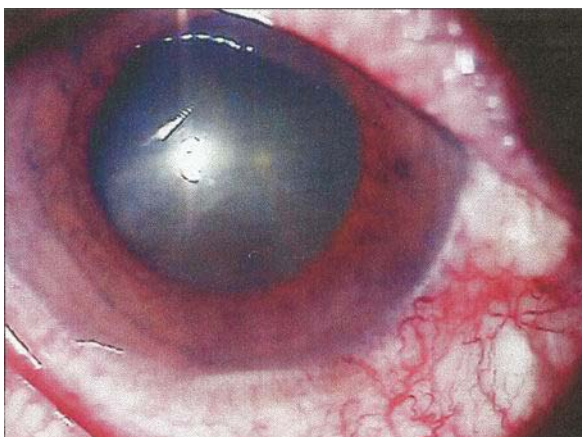


Figure 5. A case of bilateral endogenous endophthalmitis caused by *P. agglomerans* in a patient with interstitial lung disease. Hypopyon in the anterior chamber of the right eye. According to Seok et al. [44]

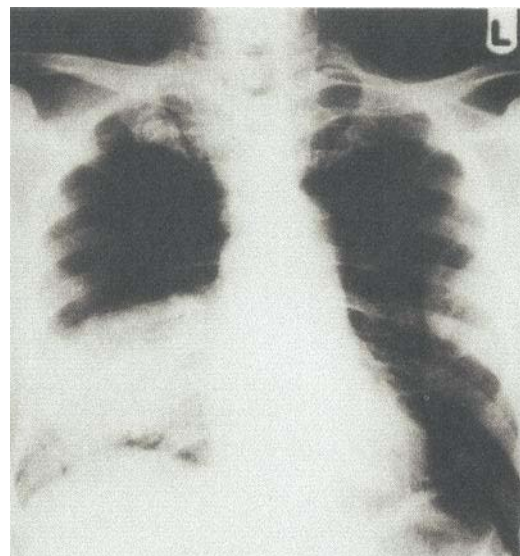


Figure 6. Fatal case of primary pneumonia caused by *P. agglomerans*. Patient's chest radiograph showing consolidation in the right middle and lower lobes. According to Al-Damluji et al. [54], with permission

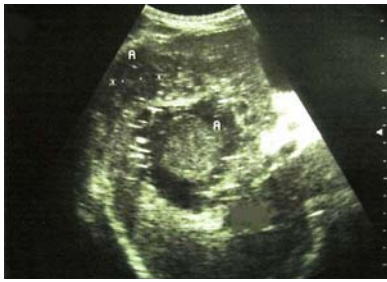

Figure 7. Pyogenic liver abscess caused by *P. agglomerans*. Upper abdominal ultrasonography shows 2 heterogeneous hypochoic images ('A') in the right lobe of the liver. According to Rodrigues et al. [57], with permission

microbiota in chronic periodontitis lesions, posing a risk of systemic infections particularly in immunocompromised and hospitalized hosts.

In conclusion, the infections caused by *P. agglomerans* reveal a diverse clinical picture and have an opportunistic character, occurring mostly in immunocompromised persons. In the majority of cases, the clinical course of the disease is mild and application of the proper antibiotic treatment leads to full recovery [37, 38]. This underscores the need to consider *P. agglomerans* as a possible causative factor of various atypical infections, mostly those hospital-acquired or preceded by injury with plant material.

Causative agent of infections in animals

Compared to humans, there are only few reports on infections caused by *Pantoea agglomerans* in vertebrate animals. Gibson et al. [60] has identified *P. agglomerans* as a possible cause of equine abortion on the basis of positive cultures from aborted foetuses and/or foetal membranes associated with the presence of inflammatory lesions, mostly appearing as interstitial pneumonia, which had been evidenced by histopathological examination. Considering the known affinity of *P. agglomerans* to mammalian macrophages [55], the electron micrograph reproduced by authors is very meaningful, showing numerous bacteria engulfed within a cytoplasmic vacuole of an alveolar macrophage of aborted foetus (Fig. 8). Hong et al. [61] identified *P. agglomerans* as a one of the causative agents of equine placentitis; however, its prevalence in the placentas from aborted, stillborn, and premature foals examined by these authors was smaller compared to other bacterial and fungal pathogens.

Pantoea agglomerans has been identified by Pomorski et al. [55, 62] as a potential cause of allergic pulmonary diseases in cows; however, to the best of our knowledge, no infectious diseases evoked by this bacterium were described until recently in these animals. Verdier-Metz et al. [63] isolated *P. agglomerans* and *Pantoea* sp. from the teat skin of healthy cows, without any pathologic changes.

Little is known about the occurrence of *P. agglomerans* in birds. Kisková et al. [64] reported a common occurrence of this species in the digestive tract of dunnocks (*Prunella modularis*) in Slovakia. *P. agglomerans* was found to occur also in fishes. It was isolated by Hansen et al. [65] from the kidney of a dolphin fish (*Coryphaena hippurus*), and identified as the cause of a haemorrhagic disease in this species, leading to marked economic losses. The bacterium was also

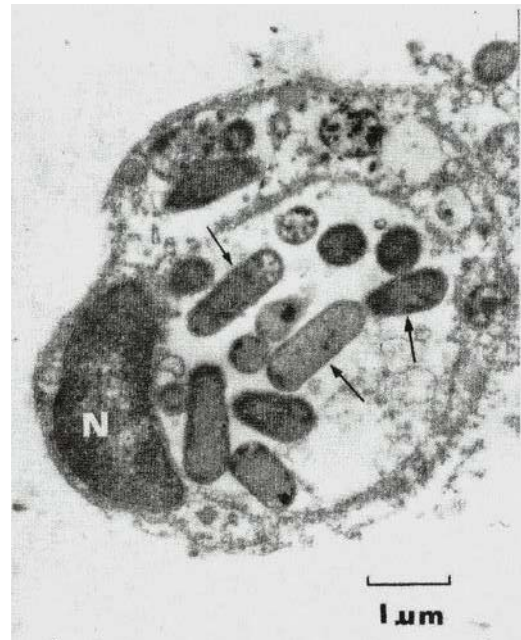


Figure 8. Electron microscopy of ultra-thin lung sections of aborted equine foetus stained with uranyl acetate and lead citrate. Bacteria corresponding to *P. agglomerans* (marked with arrows) are engulfed within a cytoplasmic vacuole of an alveolar macrophage. N – nucleus, $\times 12,500$. According to Gibson et al. [60], with permission

isolated from brown and rainbow trout [66, 67], but in these cases it seems to have played a positive role, as a potential antagonist of the pathogen *Saprolegnia parasitica*.

Pantoea agglomerans strains occur commonly – usually as symbionts – in arthropods, mostly insects [68]. Among others, they were found to be associated with social insects, such as bees [69, 70], ants [71], and termites [72]. N_2 -fixing *P. agglomerans* strains found in the guts of wood-eating termites were identified as a potential source of nitrogen for these insects [72]. So far, much attention has been paid to the occurrence of *P. agglomerans* in insect vectors of plant, animal and human diseases [73, 74], which will be discussed in detail later in this article and in the next article describing the beneficial effects of *P. agglomerans*. *Pantoea agglomerans* occurs commonly as a mutualist (in this form of symbiosis benefit both organisms: bacterium as well as insect host) in the gut of locusts (*Schistocerca gregaria*), and is probably involved in the synthesis of an insect cohesion pheromone which increases the risk of swarming and locust plague [75]. Apart from insects, *P. agglomerans* has also been isolated from the representatives of other arthropod taxa, such as ticks *Dermaacentor reticulatus* (class Arachnida) [76], crabs *Ucides cordatus* (subphylum Crustacea) [77], and millipedes *Cylindroiulus caeruleocinctus* and *Ommatoiulus sabulosus* (class Diplopoda) [78]. Much less is known about the occurrence of *P. agglomerans* in invertebrates other than arthropods; Nadarasah and Stavrinides [79] reported the isolation of this bacterium from a slug (shell-less gastropod mollusc) in Canada.

Plant and mushroom pathogen

Pantoea agglomerans usually occurs in plants as an epi- or endophytic symbiont, often as mutualist. Nevertheless, this species has also been identified as a cause of plant diseases,

such as opportunistic bacterial seed and boll rot of cotton (*Gossypium hirsutum*) grown in the field (Fig. 9) [80]. The disease has been reported to be responsible for losses of 10–15% of cotton yield in the south-eastern US Cotton Belt. Pathogenic bacteria could be transmitted into cotton bolls by the southern green stink bug (*Nezara viridula*; Heteroptera: Pentatomidae) (Fig. 10) [73]. *P. agglomerans* and *P. ananatis* cause another plant disease: a centre rot of sweet onion (*Allium cepa*). Also in this case, the pathogens were transmitted by insect vectors, namely the onion thrips (*Thrips tabaci*; Thysanoptera: Thripidae) [81]. *P. agglomerans* was also shown to cause diseases of other plants, such as: • bacterial damage to the various organs of grass species, including pest species called couch grass (*Elytrigia repens*), and cultivable grass called onion couch (*Arrhenatherum elatius*) [82]; • black spot necrosis of the leaves of beach pea (*Lathyrus maritimus*) growing on the shorelines of Newfoundland, Canada [83]; • bacterial spot disease of Chinese taro (*Alocasia cucullata*), an ornamental species commonly cultivated in Brazil [84]; • reduction of the growth of bamboo (*Guadua angustifolia*) shoots cultured *in vitro* [85]; • brown apical necrosis of walnut (*Juglans regia*) in China [86]; • leaf blight and vascular wilt in maize (*Zea mays*) and sorghum (*Sorghum bicolor*) in Mexico [87]; • leaf blight in rice (*Oryza sativa*) in Korea [88]. *P. agglomerans* has been originally described by Kim et al. [89] as a cause of the brown discoloration of the inner glume (palea) of rice; however, subsequent investigations [90, 91] showed that the true disease agent was *Pantoea ananatis*, a related species.

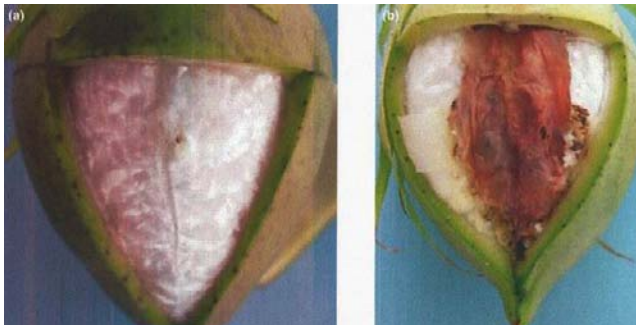

Figure 9. Disease of cotton bolls caused by *P. agglomerans*. (a) Control boll injected with PO4 buffer showing no apparent infection symptoms. (b) Boll injected with *P. agglomerans* strain Sc1-R showing disease symptoms 2 weeks post-inoculation. According to Medrano and Bell [80], with permission

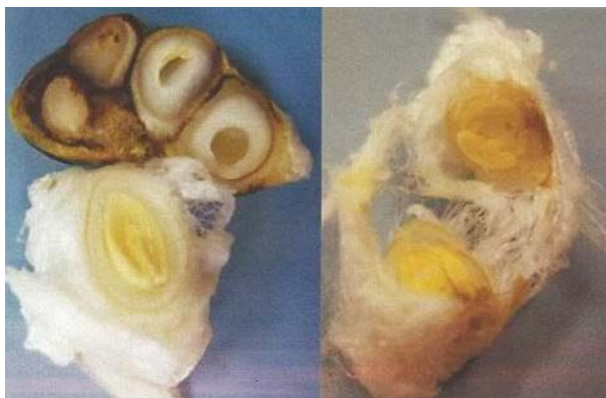

Figure 10. Differences in seed development in cotton bolls depending on exposure to vector insect *Nezara viridula* harbouring *P. agglomerans*. Left: A seed with evidence of feeding by a vector harbouring *P. agglomerans* showing pathologic changes (top), and seed from a boll caged without insect showing no changes (bottom). Right: seeds from a boll with signs of feeding by a vector not harbouring *P. agglomerans*, without pathologic changes. According to Medrano et al. [73], with permission

Some plant-pathogenic strains of *P. agglomerans* are tumourigenic, inducing gall formation on gypsophila, beet, wisteria, Douglas-fir and cranberry [92, 93]. The best known are strains *P. agglomerans* pv. (pathovar) *gypsophila* forming galls on the ornamental plant gypsophila (*Gypsophila paniculata*) and *P. agglomerans* pv. *betae*, which incites galls on both table beet (*Beta vulgaris*) and gypsophila (Fig. 11). Both these pathovars are supposed to evolve from symbionts to pathogens, and complex determinants of their pathogenicity were intensively studied by a group of Israeli scientists [93, 94, 95, 96, 97]. They showed that *P. agglomerans* was transformed into a host-specific tumourigenic pathogen by acquiring a 150 kb pPATH plasmid containing a pathogenicity island [95]. Gall formation by *P. agglomerans* pv. *gypsophila* is controlled by the hypersensitive response and pathogenicity (*hrp*) system, phytohormones, and the quorum-sensing (QS) system [94, 96, 97]. QS is a feedback system regulating life functions of bacteria and interrelations between bacterium and host, depending on the density of bacterial colonizer, which is steered by a diffusible signal molecule targeting various functions, usually Acyl-homoserine lactone (AHL) [94]. The major role of the QS system in governing the colonization of maize by *Pantoea stewartii* subsp. *stewartii*, the species related to *P. agglomerans*, was evidenced by Koutsoudis et al. [98].



Figure 11. Galls on cuttings of the ornamental plant gypsophila (*Gypsophila paniculata*) incited by *P. agglomerans* pv. *gypsophila* (on left) and *P. agglomerans* pv. *betae* (on right). According to Manulis and Barash [93], with permission

Interesting multispecies interactions were recently described by Buonauro et al. [99] who noted that *P. agglomerans* strains which normally exist in olive trees as harmless endophytes, may cooperate with the bacterial pathogen *Pseudomonas savastanoi* pv. *savastanoi*, causing the olive knot disease by the formation of stable bacterial consortia and exchange of QS signals, which increases the severity of the disease.

Pantoea strains may be also pathogenic for mushrooms. Ma et al. [100] have identified *Pantoea* as a cause of bacterial blight disease in the edible mushroom *Pleurotus eryngii* cultivated in Beijing, China. The pathogenic isolates were initially determined as close to *P. agglomerans*, but a more detailed genetic examination enabled the authors to classify them as belonging to a novel species, described as *Pantoea pleuroti*.

Ice nucleation activity

Pantoea agglomerans, together with *Pseudomonas syringae* and *Pseudomonas fluorescens*, reveals unique ice nucleation activity, e.g. creating the structures called ice nuclei that initiate the forming of the tissue-destructing ice crystals on the surface of plants, leading to frost injury of plants at temperatures at which such injury normally does not occur (usually between -2°C – -5°C) [101, 102]. In the experiments performed by Lindow et al. [101], different plants (tobacco, bean, lettuce, marigold, eggplant, sunflower, tomato, zinnia, pumpkin, cucumber) sprayed with a suspension of *P. agglomerans* were almost completely killed after freezing at -5°C , while no damage to plants sprayed with the buffer alone was observed. Kim et al. [89] observed that the *P. agglomerans* strain pathogenic for rice (which probably should be reclassified as belonging to the closely-related species *P. ananatis*) had a high ice nucleation activity. Corn seedlings sprayed with the cell suspension of this strain were frost-damaged already at excessively high temperatures ranging from -1°C to -2°C . It has been found that the ice nuclei produced by *P. agglomerans* are shed from the outer membrane of bacteria in the form of protein-containing vesicles measuring 50–300 nm [102, 103], that resemble structures described by us as endotoxin-containing vesicles [55, 104].

Determinants of pathogenicity and of other traits of *Pantoea agglomerans*

The genomes of 7 *P. agglomerans* strains isolated from various sources and showing various properties, both pathogenic and beneficial, were sequenced and published [105, 106, 107, 108, 109, 110, 111]. The sizes of the genomes and their G+C contents were within fairly narrow ranges 4.58–5.00 Mb and 54.3–55.05%, respectively. The availability of these genomes, as well as the genomes from the other species belonging to genus *Pantoea*, has contributed to a better understanding of the host colonizing and metabolic properties, as well as the underlying genetic and physiologic mechanisms revealed by the strains belonging to this highly versatile genus [68]. Considering this versatility, Walterson and Stavriniades [68] expressed an opinion that these mechanisms have only been partly explored, and their complete characteristics, enabling full knowledge of the pathogenic and beneficial traits of *Pantoea*, might be possible after the description of more genomes extracted from various strains of this genus.

A large number of new species belonging to *Pantoea* genus was recently described and there is a possibility that some *P. agglomerans* strains identified in the past as inducers of human, animal or plant diseases could now be classified within new taxa [68, 79, 112]. Hence, it would probably be safer in some cases to define the described infectious diseases as caused by bacteria belonging the 'Pantoea agglomerans complex'. Nevertheless, in the light of the studies by Delétoile et al. [113], Völksch et al. [114], and a recent experimental study by Nadarasah and Stavriniades [79] who examined the development of 115 *Pantoea* strains isolated from various sources in the plant and animal hosts, the classification of a *Pantoea* strain within a given species does not necessarily predetermine its specific pathogenicity, as the strains belonging to this genus show a broad host range resulting in capability of plant isolates to infect animals and *vice versa*.

Genes encoding proteins determining pathogenicity and other traits of *Pantoea agglomerans* and other species of *Pantoea* genus are often located in plasmids, such as the above-mentioned 150 kb pPATH plasmid of *P. agglomerans* containing a pathogenicity island determining tumour formation on plants [95]. De Maayer et al. [115] described the Large *Pantoea* Plasmid (LPP-1) that is common for all *Pantoea* species identified to date, and determines the basic life functions of the bacterium, such as transport and catabolism of various substrates, inorganic ion assimilation, resistance to antibiotics and heavy metals, colonization and persistence in the host and environment, pathogenesis and antibiosis. LPP-1 directs also the diversification of these functions, depending on the *Pantoea* strain and species. The authors expressed an opinion that the LPP-1 encodes proteins responsible for adaptation of particular *Pantoea* strains to various ecological niches and for many of their functions which could be classified from the human viewpoint both as deleterious (pathogenicity for plants, animals and humans) and beneficial (plant-growth promoting, antibiotic production, biocontrol of plant pests, environment remediation) [115]. In some cases, certain pathogenic properties of *Pantoea* strains, such as an interaction with a specific host, could be directed by genetic entities much smaller than plasmids or pathogenicity genomic islands. An example could be *P. agglomerans* T3SEs effector proteins of the type III secretion system which are encoded by genome regions, the nucleotide sequences smaller than the gene [116, 117].

The type III secretion system (T3SS) is one of the important determinants of pathogenicity. This is an extracellular apparatus used by many Gram-negative bacteria to deliver effector proteins (T3SEs) with the use of needle-like injectisomes or pili directly into the cytosol of plant and animal cells in order to modulate host cell defences, enabling successful pathogen colonization and growth [117, 118, 119]. The presence of T3SS has been detected in the *Pantoea* species, including *P. agglomerans* [116, 117] and related species *Pantoea stewartii* subsp. *stewartii*, the causative agent of Stewart's bacterial wilt and leaf blight of maize [118]. Correa et al. [118] demonstrated that the latter species uses 2 T3SS systems, denoted as PSI-1 (*Pantoea* secretion island – 1) and PSI-2, the first for successful colonization of maize and the second for colonization of the flea beetle vector (*Chaetocnema pulicaria*). Kirzinger et al. [119] discovered in *Pantoea stewartii* subsp. *stewartii* the presence of a third T3SS system, similar to that present in *Salmonella*, which they called PSI-3. The authors expressed an opinion that whereas PSI-1 and to a lesser extent PSI-2, is inherited vertically by evolutionary processes, the PSI-3 is acquired by *Pantoea* species horizontally, by contemporary genetic exchange with other members of the Enterobacteriaceae, including genera whose members are known human pathogens, such as *Salmonella* and *Yersinia*. This could explain, at least in part, the ability of the particular *Pantoea* strains to infect humans and vertebrate animals.

Concluding remarks

Pantoea agglomerans appears to be a relatively well-known causative agent of the opportunistic human infections, mostly in immunocompromised individuals. Nevertheless, although the exact data were unless recently unknown, the prevalence of these infections is presumably lower compared

to the cases of allergic and/or immunotoxic disorders caused by this bacterium. The latter are much less explored on the world scale, but most probably pose more important medical problems, especially with relation to occupational health [55, 120].

P. agglomerans is widespread among invertebrate and vertebrate animals, but its clinical significance in domestic and farm animals is almost unknown. Much better explored is the pathogenicity of this bacterium for plants, and some underlying mechanisms, such as quorum sensing and type III secretion systems, which could be also considered in the analysis of animal and human infections. The effects of *P. agglomerans* on infected plants could be increased by the ice nucleation activity of this bacterium, inciting frost injury in plants at the temperatures in which such injury normally does not occur.

Acknowledgements

The authors express their thanks to following: to the John Wiley & Sons, Inc., for permission to reproduce Figure 3 from the article by Shubov et al. [26], and Figures 8–11 from the articles by Gibson et al. [60], Medrano and Bell [80], Medrano et al. [73] and Manulis and Barash [93], all Figures protected by Copyright © John Wiley & Sons, All Rights Reserved; to the BMJ Publishing Group Ltd. for permission to reproduce Figure 2 from the article by Kratz et al. [11], and Figure 6 from the article by Al-Damluji et al. [54]; to the Elsevier B.V. for permission to reproduce Figure 1 from the article by Oleginski et al. [4], and to the Editors of *Tropical Gastroenterology* for permission to reproduce Figure 7 from the article by Rodrigues et al. [57].

REFERENCES

- Pien FD, Martin WJ, Hermans PE, Washington JA. Clinical and bacteriologic observations on the proposed species *Enterobacter agglomerans* (the herbicola-lathyri bacteria). *Mayo Clin Proc.* 1972; 47: 739–745.
- Jain S, Bohra I, Mahajan R, Jain S, Chugh TD. *Pantoea agglomerans* infection behaving like a tumor after plant thorn injury: an unusual presentation. *Indian J Pathol Microbiol.* 2012; 55(3): 386–388.
- Mason GI, Bottone EJ, Podos SM. Traumatic endophthalmitis caused by an *Erwinia* species. *Am J Ophthalmol.* 1976; 82(5): 709–713.
- Oleginski TP, Bush DC, Harrington TM. Plant thorn synovitis: an uncommon cause of monoarthritis. *Semin Arthritis Rheum.* 1991; 21(1): 40–46.
- Duerinckx JF. Case report: subacute synovitis of the knee after a rose thorn injury: unusual clinical picture. *Clin Orthop Relat Res.* 2008; 466(12): 3138–3142.
- Lee NE, Chung IY, Park JM. A case of *Pantoea* endophthalmitis. *Korean J Ophthalmol.* 2010; 24(5): 318–321.
- Flatauer FE, Khan MA. Septic arthritis caused by *Enterobacter agglomerans*. *Arch Intern Med.* 1978; 138(5): 788.
- Rosenfeld R, Spiegelblatt L, Chicoine R, Laverdiere M. Thorn-induced periostitis associated with *Enterobacter agglomerans* infection. *Can Med Assoc J.* 1978; 119(8): 925–928.
- Strömquist B, Edlund E, Lidgren L. A case of blackthorn synovitis. *Acta Orthop Scand.* 1985; 56(4): 342–343.
- De Champs C, Le Seaux S, Dubost JJ, Boisgard S, Sauvezie B, Sirot J. Isolation of *Pantoea agglomerans* in two cases of septic monoarthritis after plant thorn and wood sliver injuries. *J Clin Microbiol.* 2000; 38(1): 460–461.
- Kratz A, Greenberg D, Barki Y, Cohen E, Lifshitz M. *Pantoea agglomerans* as a cause of septic arthritis after palm tree thorn injury; case report and literature review. *Arch Dis Child.* 2003; 88(6): 542–544.
- Ulloa-Gutierrez R, Moya T, Avila-Aguero ML. *Pantoea agglomerans* and thorn-associated suppurative arthritis. *Pediatr Infect Dis J.* 2004; 23(7): 690.
- Rave O, Assous MV, Hashkes PJ, Lebel E, Hadas-Halpern I, Megged O. *Pantoea agglomerans* foreign body-induced septic arthritis. *Pediatr Infect Dis J.* 2012; 31(12): 1311–1312.
- Vaiman M, Abuia R, Lazarovich T, Lotan G. *Pantoea agglomerans* as an indicator of a foreign body of plant origin in cases of wound infection. *J Wound Care.* 2013; 22: 182–185.
- Sudhalkar A, Majji AB, Chhablani J, Manderwad G. *Pantoea agglomerans* endophthalmitis: clinical features and outcomes. *Retina.* 2014; 34(8): 1702–1706.
- Venincasa VD, Kuriyan AE, Flynn HW Jr, Sridhar J, Miller D. Endophthalmitis caused by *Pantoea agglomerans*: clinical features, antibiotic sensitivities, and outcomes. *Clin Ophthalmol.* 2015; 9: 1203–1207.
- Zuberbuhler B, Carifi G, Leatherbarrow B. Acute dacryocystitis in a 2-year old child caused by *pantoea*. *Orbit.* 2012; 31(1): 13–14.
- Manoharan G, Lalitha P, Jegannathan LP, Dsilva SS, Prajna NV. *Pantoea ananatis* as a cause of corneal infiltrate after rice husk injury. *J Clin Microbiol.* 2012; 50(6): 2163–2164.
- Williams AJK, Scott RJD, Lightfoot NF. *Erwinia herbicola* as a cause of bacterial endocarditis. *J Infect.* 1986; 12: 71–73.
- Vincent K, Szabo RM. *Enterobacter agglomerans* osteomyelitis of the hand from a rose thorn. A case report. *Orthopedics.* 1988; 11(3): 465–467.
- Labianca L, Montanaro A, Turturro F, Calderaro C, Ferretti A. Osteomyelitis caused by *Pantoea agglomerans* in a closed fracture in a child. *Orthopedics.* 2013; 36(2):e252–256.
- Laporte C, Demachy MC, Thevenin-Lemoine C. Tibial osteitis caused by *Pantoea agglomerans* after open grade IIIB tibial shaft fracture. *Rev Chir Orthop Reparatrice Appar Mot.* 2002; 88(6): 625–627 (in French).
- Maki DG, Rhame FS, Mackel DC, Bennett JV. Nationwide epidemic of septicemia caused by contaminated intravenous products. I. Epidemiologic and clinical features. *Am J Med.* 1976; 60: 471–485.
- Matsaniotis NS, Syriopoulou VP, Theodoridou MC, Tzanetou KG, Mostrou GI. *Enterobacter* sepsis in infants and children due to contaminated intravenous fluids. *Infect Control.* 1984; 5(10): 471–477.
- Van Rostenberghe H, Noraida R, Wan Pauzi WI, Habsah H, Zeehaida M, Rosliza AR, Fatimah I, Nik Sharimah NY, Maimunah H. The clinical picture of neonatal infection with *Pantoea* species. *Jpn J Infect Dis.* 2006; 59(2): 120–121.
- Shubov A, Jagannathan P, Chin-Hong PV. *Pantoea agglomerans* pneumonia in a heart-lung transplant recipient: case report and a review of an emerging pathogen in immunocompromised hosts. *Transpl Infect Dis.* 2011; 13(5): 536–539.
- Rasmussen SW, Koczulab B. Transfusion associated bacteremia and septic shock due to *Erwinia herbicola*. *Scand J Infect Dis.* 1992; 24(2): 241–243.
- Boszczowski I, Nóbrega de Almeida Júnior J, Peixoto de Miranda EJ, Pinheiro Freire M, Guimarães T, Chaves CE, Cais DP, Strabelli TM, Risek CF, Soares RE, Rossi F, Costa SF, Levin AS. Nosocomial outbreak of *Pantoea agglomerans* bacteraemia associated with contaminated anticoagulant citrate dextrose solution: new name, old bug? *J Hosp Infect.* 2012; 80(3): 255–258.
- Habsah H, Zeehaida M, Van Rostenberghe H, Noraida R, Wan Pauzi WI, Fatimah I, Rosliza AR, Nik Sharimah NY, Maimunah H. An outbreak of *Pantoea* spp. in a neonatal intensive care unit secondary to contaminated parenteral nutrition. *J Hosp Infect.* 2005; 61(3): 213–218.
- Bicudo EL, Macedo VO, Carrara MA, Castro FF, Rage RI. Nosocomial outbreak of *Pantoea agglomerans* in a pediatric urgent care center. *Braz J Infect Dis.* 2007; 11(2): 281–284.
- Cruz AT, Cazacu AC, Allen CH. *Pantoea agglomerans*, a plant pathogen causing human disease. *J Clin Microbiol.* 2007; 45(6): 1989–1992.
- Kurşun O, Unal N, Cesur S, Altın N, Canbakan B, Argun C, Koldaş K, Sencan I. A case of ventilator-associated pneumonia due to *Pantoea agglomerans*. *Mikrobiyol Bul.* 2012; 46(2): 295–298 (in Turkish).
- Izzo I, Lania D, Castro A, Lanzini F, Bella D, Pagani A, Colombini P. Seven cases of port-a-cath contamination caused by *Pantoea agglomerans* in the Oncological Service of Iseo Hospital, Brescia (Italy). *Infez Med.* 2014; 22(2): 152–155 (in Italian).
- Hrabińska-Zachwieja J, Krukowski J, Tubek S, Zeljaś A. Bacterial endocarditis caused by *Enterobacter agglomerans* in a patient with mitral valve leaflet prolapse. *Wiad Lek.* 1989; 42(7): 453–455 (in Polish).
- Bergman KA, Arends JP, Schölvinck EH. *Pantoea agglomerans* septicemia in three newborn infants. *Pediatr Infect Dis J.* 2007; 26(5): 453–454.
- Aly NY, Salmeen HN, Lila RA, Nagaraja PA. *Pantoea agglomerans* bloodstream infection in preterm neonates. *Med Princ Pract.* 2008; 17(6): 500–503.

37. Habhab W, Blake PG. *Pantoea* peritonitis: not just a "thorny" problem. *Perit Dial Int*. 2008; 28(4): 430.
38. Cheng A, Liu C-Y, Tsai H-Y, Hsu M-S, Yang C-J, Huang Y-T, Liao C-H, Hsueh P-R. Bacteremia caused by *Pantoea agglomerans* at a medical center in Taiwan, 2000–2010. *J Microbiol Immunol Infection*. 2013; 46: 187–194.
39. Cicchetti R, Iacobini M, Midulla F, Papoff P, Mancuso M, Moretti C. *Pantoea agglomerans* sepsis after rotavirus gastroenteritis. *Pediatr Infect Dis J*. 2006; 25(3): 280–281.
40. Christakis GB, Perlorentzou SP, Aslanidou M, Savva L, Zarkadis IK. Bacteremia caused by *Pantoea agglomerans* and *Enterococcus faecalis* in a patient with colon cancer. *J BUON*. 2007; 12(2): 287–290.
41. Liberto MC, Matera G, Puccio R, Lo Russo T, Colosimo E, Focà E. Six cases of sepsis caused by *Pantoea agglomerans* in a teaching hospital. *New Microbiol*. 2009; 32(1): 119–123.
42. Wang J, Fraser JF. An Intracranial Petri Dish? Formation of Abscess in Prior Large Stroke After Decompressive Hemicraniectomy. *World Neurosurg*. 2015; 84(5): 1495.e5–9.
43. Hischebeth GT, Kohlhof H, Wimmer MD, Randau TM, Bekeredjian-Ding I, Gravius S. Detection of *Pantoea agglomerans* in hip prosthetic infection by sonication of the removed prosthesis: the first reported case. *Technol Health Care*. 2013; 21(6): 613–618.
44. Seok S, Jang YJ, Lee SW, Kim HC, Ha GY. A case of bilateral endogenous *Pantoea agglomerans* endophthalmitis with interstitial lung disease. *Korean J Ophthalmol*. 2010; 24(4): 249–51.
45. Kletke SN, Brissette AR, Gale J. Endogenous bacterial endophthalmitis caused by *Pantoea* species: a case report. *Can J Ophthalmol*. 2014; 49(1): e1–2. doi: 10.1016/j.cjco.2013.09.004.
46. Flores Popoca EO, Garcia MM, Figueroa SR, Medellín AM, Trujillo HS, Rojas HVS, Durán NR. Clinical study: *Pantoea agglomerans* in immunodeficient patients with different respiratory symptoms. *Scien World J* 2012; 2012:156827, doi: 10.1100/2012/156827.
47. Lim PS, Chen SL, Tsai CY, Pai MA. *Pantoea* peritonitis in a patient receiving chronic ambulatory peritoneal dialysis. *Nephrology*. 2006; 11(2): 97–99.
48. Magnette C, Tintillier M, Horlait G, Cuvelier C, Pochet JM. Severe peritonitis due to *Pantoea agglomerans* in a CCPD patient. *Perit Dial Int*. 2008; 28(2): 207–208.
49. Ferrantino M, Navaneethan SD, Sloan JA. *Pantoea agglomerans*: an unusual inciting agent in peritonitis. *Perit Dial Int*. 2008; 28(4): 428–430.
50. Borràs M, Roig J, Garcia M, Fernández E. Adverse effects of *Pantoea* peritonitis on peritoneal transport. *Perit Dial Int*. 2009; 29(2): 234–235.
51. Kazancioglu R, Buyukaydin B, Iraz M, Alay M, Erkoc R. An unusual cause of peritonitis in peritoneal dialysis patients: *Pantoea agglomerans*. *J Infect Dev Ctries*. 2014; 8(7): 919–922.
52. Naha K, Ramamoorthi, Prabhu M. Spontaneous septicaemia with multi-organ dysfunction – a new face for *Pantoea agglomerans*? *Asian Pacific J Trop Med*. 2012; 5(1): 83–84.
53. García-Pardo G, Martí N, Vidal F, Richart C. *Enterobacter agglomerans* pneumonia outside of the hospital in a previously healthy patient. *Enferm Infecc Microbiol Clin*. 1999; 17(1): 48 (in Spanish).
54. Al-Damliji S, Dickinson CM, Beck A. *Enterobacter agglomerans*: a new cause of primary pneumonia. *Thorax*. 1982; 37(11): 865–866.
55. Dutkiewicz J, Mackiewicz B, Lemieszek MK, Golec M, Skórska C, Góra-Florek A, Milanowski J. *Pantoea agglomerans*: a mysterious bacterium of evil and good. Part II. Deleterious effects: Dust-borne endotoxins and allergens – focus on grain dust, other agricultural dusts and wood dust. *Ann Agric Environ Med*. 2016; 23(1): 110–133.
56. Porter P, Wray CC. *Enterobacter agglomerans* spondylodiscitis: a possible, unrecognized complication of tetracycline therapy. *Spine*. 2000; 25(10): 1287–1289.
57. Rodrigues AL, Lima IK, Koury A Jr, de Sousa RM, Meguins LC. *Pantoea agglomerans* liver abscess in a resident of Brazilian Amazonia. *Trop Gastroenterol*. 2009; 30(3): 154–155.
58. Fullerton DG, Lwin AA, Lal S. *Pantoea agglomerans* liver abscess presenting with a painful thigh. *Eur J Gastroenterol Hepatol*. 2007; 19(5): 433–435.
59. Gonçalves MO, Coutinho-Filho WP, Pimenta FP, Pereira GA, Pereira JA, Mattos-Guaraldi AL, Hirata R Jr. Periodontal disease as reservoir for multi-resistant and hydrolytic enterobacterial species. *Lett Appl Microbiol*. 2007; 44(5): 488–494.
60. Gibson JA, Eaves LE, O'Sullivan BM. Equine abortion associated with *Enterobacter agglomerans*. *Equine Vet J*. 1982; 14(2): 122–125.
61. Hong CB, Donahue JM, Giles RC, Jr, Petrites-Murphy MB, Poonacha KB, Roberts AW, Smith BJ, Tramontin RR, Tuttle PA, Swerczek TW. Etiology and pathology of equine placentitis. *J Vet Diagn Invest*. 1993; 5: 56–63.
62. Pomorski ZJH, Dutkiewicz J, Taszkun I, Woźniak M, Sitkowski W, Skórska C, Cholewa G. Studies on allergic conditioning of cattle pneumopathy, resulting from breathing in pneumoallergens comprised in organic dusts. *Ann UMCS (Sectio DD)*. 1993; 48: 183–193 (in Polish).
63. Verdier-Metz I, Gagne G, Bornes S, Monsallier F, Veisseire P, Delbès-Paus C, Montel MC. Cow teat skin, a potential source of diverse microbial populations for cheese production. *Appl Environ Microbiol*. 2012; 78(2): 326–333.
64. Kisková J, Hrehová Z, Janiga M, Lukáš M, Haas M, Čuvalová Z. Bacterial prevalence in the Dunnock (*Prunella modularis*) in sub-alpine habitats of the Western Carpathians, Slovak Republik. *Ornis Fennica*. 2012; 89: 34–43.
65. Hansen GH, Raa J, Olafsen JA. Isolation of *Enterobacter agglomerans* from dolphin fish, *Coryphaena hippurus* L. *J Fish Dis*. 1990; 13: 93–96.
66. Loch TP, Faisal M. Isolation of *Pantoea agglomerans* from brown trout (*Salmo trutta*) from Gilchrist Creek, Michigan, USA. *Bull Europ Assoc Fish Pathol*. 2007; 27(5): 200–204.
67. Carbajal-González MT, Fregeneda-Grandes JM, Suárez-Ramos S, Rodríguez Cadenas F, Aller-Gancedo JM. Bacterial skin flora variation and in vitro inhibitory activity against *Saprolegnia parasitica* in brown and rainbow trout. *Dis Aquat Organ*. 2011; 96(2): 125–135.
68. Walterson AM, Stavriniades J. *Pantoea*: insights into a highly versatile and diverse genus within the Enterobacteriaceae. *FEMS Microbiol Rev*. 2015; 39: 968–984.
69. Lončarić I, Heigl H, Lick E, Moosbeckhofer R, Busse H-J, Rosengarten R. Typing of *Pantoea agglomerans* isolated from colonies of honey bees (*Apis mellifera*) and culturability of selected strains from honey. *Apidologie*. 2009; 40: 40–54.
70. Lozo J, Berić T, Terzić-Vidojević A, Stanković S, Fira D, Stanisavljević L. Microbiota associated with pollen, bee bread, larvae and adults of solitary bee *Osmia cornuta* (Hymenoptera: Megachilidae). *Bull Entomol Res*. 2015; 105(4): 470–476.
71. Suen G, Scott JJ, Aylward FO, Adams SM, Tringe SG, Pinto-Toma's AA, Foster CE, Pauly M, Weimer PJ, Barry KW, Goodwin LA, Bouffard P, Li11 L, Osterberger J, Harkins TT, Slater SC, Donohue TJ, Curriel CR. An insect herbivore microbiome with high plant biomass-degrading capacity. *PLoS Genet*. 2010; 6(9): e1001129. doi: 10.1371/journal.pgen.1001129
72. Potrikus CJ, Breznak JA. Nitrogen-fixing *Enterobacter agglomerans* isolated from guts of wood-eating termites. *Appl Environ Microbiol*. 1977; 33(2): 392–399.
73. Medrano EG, Esquivel JF, Bell AA. Transmission of cotton seed and boll rotting bacteria by the southern green stink bug (*Nezara viridula* L.). *J Appl Microbiol*. 2007; 103(2): 436–444.
74. Wang S, Ghosh AK, Bongio N, Stebbings KA, Lampe DJ, Jacobs-Lorena M. Fighting malaria with engineered symbiotic bacteria from vector mosquitoes. *Proc Natl Acad Sci U S A*. 2012; 109(31): 12734–12739.
75. Dillon RJ, Vennard CT, Charnley AK. A note: gut bacteria produce components of a locust cohesion pheromone. *J Appl Microbiol*. 2002; 92(4): 759–763.
76. Dutkiewicz J. Studies on endotoxins of *Erwinia herbicola* and their biological activity. *Zbl Bakt Hyg I Abt Orig A*. 1976; 236: 487–508.
77. Vieira RHS, de Lima EA, Sousa DBR, dos Reis EF, Costa RG, Rodrigues DP. *Vibrio* spp. and *Salmonella* spp., presence and susceptibility in crabs *Ucides cordatus*. *Rev Inst Med Trop S Paulo*. 2004; 46(4): 179–182.
78. Kania G, Kłapeć T. Seasonal activity of millipedes (Diplopoda) – their economic and medical significance. *Ann Agric Environ Med*. 2012; 19(4): 646–650.
79. Nadarasah G, Stavriniades J. Quantitative evaluation of the host-colonizing capabilities of the enteric bacterium *Pantoea* using plant and insect hosts. *Microbiology*. 2014; 160: 602–615.
80. Medrano EG, Bell AA. Role of *Pantoea agglomerans* in opportunistic bacterial seed and boll rot of cotton (*Gossypium hirsutum*) grown in the field. *J Appl Microbiol*. 2007; 102(1): 134–143.
81. Dutta B, Barman AK, Srinivasan R, Avci U, Ullman DE, Langston DB, Gitaitis RD. Transmission of *Pantoea ananatis* and *P. agglomerans*, causal agents of center rot of onion (*Allium cepa*), by onion thrips (*Thrips tabaci*) through feces. *Phytopathology*. 2014; 104(8): 812–819.
82. Gvozdiak RI, Iakovleva LM. *Pantoea agglomerans* – pathogen of *Elytrigia repens* and *Arrhenatherum elatius* diseases. *Mikrobiol Z*. 2007; 69(1): 61–67 (in Russian).
83. Madhukar B, Khetmalas, Arya K, Bal, Lisa D, Noble, John A. Gow. *Pantoea agglomerans* is the etiologic agent for black spot necrosis on beach peas. *Can J Microbiol*. 1996, 42(12): 1252–1257.

84. Romeiro RS, Macagnan D, Mendonça HL, Rodrigues Neto J. Bacterial spot of Chinese taro (*Alocasia cucullata*) in Brazil induced by *Pantoea agglomerans*. *Plant Pathol.* 2007; 56: 1038. doi: 10.1111/j.1365-3059.2007.01631.
85. Nadha HK, Salwan R, Kasana RC, Anand M, Sood A. Identification and elimination of bacterial contamination during in vitro propagation of *Guadua angustifolia* Kunth. *Pharmacogn Mag.* 2012; 8(30): 93-97.
86. Yang KQ, Qu WW, Liu X, Liu HX, Hou LQ. First report of *Pantoea agglomerans* causing brown apical necrosis of walnut in China. *Plant Dis.* 2011; 95(6): 773.
87. Morales-Valenzuela G, Silva-Rojas HV, Ochoa-Martinez D, Valadez-Moctezuma E, Alarcon-Zuniga B, Zelaya-Molina LX, Cordova-Tellez L, Mendoza-Onofre L, Vaquera-Huerta H, Carballo-Carballo A, Farfan-Gomez A, Avila-Quezada G. First report of *Pantoea agglomerans* causing leaf blight and vascular wilt in maize and sorghum in Mexico. *Plant Dis.* 2007; 91(10): 1365.
88. Lee HB, Hong JP, Kim SB. First report of leaf blight caused by *Pantoea agglomerans* on rice in Korea. *Plant Dis.* 2010; 94(11): 1372.
89. Kim YC, Kim KC, Cho BH. Palea browning disease of rice caused by *Erwinia herbicola* and ice nucleation activity of the pathogenic bacteria. *Korean J Plant Pathol.* 1989; 5(1): 72-79.
90. Katsube K, Sato K, Shirakawa T, Takeda S. Occurrence of bacterial palea browning disease of rice in Iwate Prefecture. *Annual Rep Soc Plant Protect North Japan.* 1995; 46: 33-35.
91. Azegami K. Suppressive effect of bacteriophage on bacterial palea browning of rice caused by *Pantoea ananatis*. *J Gen Plant Pathol.* 2013; 79: 145-154.
92. Burr TJ, Katz BH, Abawi GS, Crosier DC. Comparison of tumorigenic strains of *Erwinia herbicola* isolated from table beet with *E. h. gypsophylae*. *Plant Dis.* 1991; 75: 855-858.
93. Manulis S, Barash I. *Pantoea agglomerans* pvs. *gypsophylae* and *betae*, recently evolved pathogens? *Mol Plant Pathol.* 2003; 4(5): 307-314.
94. Chalupowicz L(1), Manulis-Sasson S, Itkin M, Sacher A, Sessa G, Barash I. Quorum-sensing system affects gall development incited by *Pantoea agglomerans* pv. *gypsophylae*. *Mol Plant Microbe Interact.* 2008; 21(8): 1094-1105.
95. Barash I, Manulis-Sasson S. Recent evolution of bacterial pathogens: the gall-forming *Pantoea agglomerans* case. *Annu Rev Phytopathol.* 2009; 47: 133-152.
96. Chalupowicz L, Barash I, Panijel M, Sessa G, Manulis-Sasson S. Regulatory interactions between quorum-sensing, auxin, cytokinin, and the Hrp regulon in relation to gall formation and epiphytic fitness of *Pantoea agglomerans* pv. *gypsophylae*. *Mol Plant Microbe Interact.* 2009; 22(7): 849-856.
97. Panijel M, Chalupowicz L, Sessa G, Manulis-Sasson S, Barash I. Global regulatory networks control the hrp regulon of the gall-forming bacterium *Pantoea agglomerans* pv. *gypsophylae*. *Mol Plant Microbe Interact.* 2013; 26(9): 1031-1043.
98. Koutsoudis MD, Tsaltas D, Minogue TD, von Bodman SB. Quorum-sensing regulation governs bacterial adhesion, biofilm development, and host colonization in *Pantoea stewartii* subspecies *stewartii*. *Proc Natl Acad Sci U S A.* 2006; 103(15): 5983-5988.
99. Buonaurio R, Moretti C, da Silva DP, Cortese C, Ramos C, Venturi V. The olive knot disease as a model to study the role of interspecies bacterial communities in plant disease. *Front Plant Sci.* 2015; 6: 434. doi: 10.3389/fpls.2015.00434.
100. Ma Y, Yin Y, Rong C, Chen S, Liu Y, Wang S, Xu F. *Pantoea pleuroti* sp. nov., isolated from the fruiting bodies of *Pleurotus eryngii*. *Curr Microbiol.* 2016; 72(2): 207-212.
101. Lindow SE, Arny DC, Upper CD. Bacterial ice nucleation: a factor in frost injury to plants. *Plant Physiol.* 1982; 70(4): 1084-1089.
102. Phelps P, Giddings TH, Prochoda M, Fall R. Release of cell-free ice nuclei by *Erwinia herbicola*. *J Bacteriol.* 1986; 167(2): 496-502.
103. Li J, Lee TC. Enhanced production of extracellular ice nucleators from *Erwinia herbicola*. *J Gen Appl Microbiol.* 1998; 44(6): 405-413.
104. Dutkiewicz J, Tucker J, Burrell R, Olenchock SA, Schwegler-Berry D, Keller III GE, Ochalska B, Kaczmarek F, Skórska C. Ultrastructure of the endotoxin produced by Gram-negative bacteria associated with organic dusts. *System Appl Microbiol.* 1992; 15: 474-485.
105. Matsuzawa T, Mori K, Kadowaki T, Shimada M, Tashiro K, Kuhara S, Inagawa H, Soma G, Takegawa K. Genome sequence of *Pantoea agglomerans* strain IG1. *J Bacteriol.* 2012; 194(5): 1258-1259.
106. Remus-Emsermann MN, Kim EB, Marco ML, Tecón R, Leveau JH. Draft genome sequence of the phyllosphere model bacterium *Pantoea agglomerans* 299R. *Genome Announc.* 2013; 1(1): e00036-13. doi: 10.1128/genomeA.00036-13.
107. Smith DD, Kirzinger MW, Stavrinides J. Draft genome sequence of the antibiotic-producing cystic fibrosis isolate *Pantoea agglomerans* Tx10. *Genome Announc.* 2013; 1(5): e00904-13. doi: 10.1128/genomeA.00904-13.
108. Moretti C, Cortese C, Passos da Silva D, Venturi V, Torelli E, Firrao G, Buonaurio R. Draft genome sequence of a hypersensitive reaction-inducing *Pantoea agglomerans* strain isolated from olive knots caused by *Pseudomonas savastanoi* pv. *savastanoi*. *Genome Announc.* 2014; 2(4): e00774-14. doi: 10.1128/genomeA.00774-14.
109. Minogue TD, Daligault HE, Davenport KW, Bishop-Lilly KA, Bruce DC, Chain PS, Coyne SR, Chertkov O, Freitas T, Frey KG, Jaissle J, Koroleva GI, Ladner JT, Palacios GF, Redden CL, Xu Y, Johnson SL. Draft genome assemblies of *Enterobacter aerogenes* CDC 6003-71, *Enterobacter cloacae* CDC 442-68, and *Pantoea agglomerans* UA 0804-01. *Genome Announc.* 2014; 2(5): e01073-14. doi: 10.1128/genomeA.01073-14.
110. Lim JA, Lee DH, Kim BY, Heu S. Draft genome sequence of *Pantoea agglomerans* R190, a producer of antibiotics against phytopathogens and foodborne pathogens. *J Biotechnol.* 2014; 188C: 7-8. doi: 10.1016/j.jbiotec.2014.07.440.
111. Smits THM, Rezzonico F, Blom J, Goesmann A, Abelli A, Kron Morelli R, Vanneste JL, Duffy B. Draft genome sequence of the commercial biocontrol strain *Pantoea agglomerans* P10c. *Genome Announc.* 2015; 3(6): e01448-15. doi: 10.1128/genomeA.01448-15.
112. Rezzonico F, Stockwell VO, Tonolla M, Duffy B, Smits TH. *Pantoea* clinical isolates cannot be accurately assigned to species based on metabolic profiling. *Transpl Infect Dis.* 2012; 14(2): 200-221.
113. Delétoile A, Decré D, Courant S, Passet V, Audo J, Grimont P, Arlet G, Brisse S. Phylogeny and identification of *Pantoea* species and typing of *Pantoea agglomerans* strains by multilocus gene sequencing. *J Clin Microbiol.* 2009; 47(2): 300-310.
114. Völksch B, Thon S, Jacobsen ID, Gube M. Polyphasic study of plant- and clinic-associated *Pantoea agglomerans* strains reveals indistinguishable virulence potential. *Infect Genet Evol.* 2009; 9(6): 1381-1391.
115. De Maayer P, Chan WY, Blom J, Venter SN, Duffy B, Smits TH, Coutinho TA. The large universal *Pantoea* plasmid LPP-1 plays a major role in biological and ecological diversification. *BMC Genomics.* 2012; 13: 625. doi: 10.1186/1471-2164-13-625.
116. Nissan G, Manulis-Sasson S, Weinthal D, Mor H, Sessa G, Barash I. The type III effectors HsvG and HsvB of gall-forming *Pantoea agglomerans* determine host specificity and function as transcriptional activators. *Mol Microbiol.* 2006; 61(5): 1118-1131.
117. Kirzinger MWB, Stavrinides J. Host specificity determinants as a genetic continuum. *Trends Microbiol.* 2012; 20(2): 88-93.
118. Correa VR, Majerczak DR, Ammar el-D, Merighi M, Pratt RC, Hogenhout SA, Coplin DL, Redinbaugh MG. The bacterium *Pantoea stewartii* uses two different type III secretion systems to colonize its plant host and insect vector. *Appl Environ Microbiol.* 2012; 78(17): 6327-6336.
119. Kirzinger MWB, Butz CJ, Stavrinides J. Inheritance of *Pantoea* type III secretion systems through both vertical and horizontal transfer. *Mol Genet Genomics.* 2015; 290(6): 2075-2088.
120. Dutkiewicz J, Mackiewicz B, Lemieszek M, Golec M, Milanowski J. *Pantoea agglomerans*: a mysterious bacterium of evil and good. Part I. Deleterious effects: Dust-borne endotoxins and allergens - focus on cotton dust. *Ann Agric Environ Med.* 2015; *Ann Agric Environ Med.* 2015, 22(4): 576-588.