CASE REPORT

Annals of Agricultural and Environmental Medicine
www.aaem.pl

First detection of *Naegleria fowleri* in Slovakia associated with a fatal paediatric case of primary amoebic meningoencephalitis

Vojtech Boldiš[1,2,A-F] ✉, František Ondriska[1,2,A-F], Jozef Köppl[3,B-C,E], Marcel Brenner[4,B-C,E], Eva Nohýnková[5,A-F], Aneta Perglerová[5,B-C,E], Lenka Minichová[6,7,B-C,E-F], Jakub Steinhűbel[1,B-C,E-F]

[1] *Department of Parasitology, Medirex Ltd., Galvaniho, Slovak Republic*
[2] *Faculty of Health and Social Work, Trnava University, Slovak Republic*
[3] *Department of Paediatric Anaesthesiology and Intensive Care, Faculty of Medicine, Comenius University and National Institute of Children's Diseases, Slovak Republic*
[4] *Emergency Department, Comenius University and National Institute of Children's Diseases, Slovak Republic*
[5] *Department of Medical Microbiology, First Faculty of Medicine, Charles University, Czech Republic*
[6] *Institute of Virology, Biomedical Research Centre, Slovak Academy of Sciences, Slovak Republic*
[7] *Institute of Microbiology, Czech Academy of Sciences, Prague, Czech Republic*
A – Research concept and design, B – Collection and/or assembly of data, C – Data analysis and interpretation, D – Writing the article, E – Critical revision of the article, F – Final approval of the article

Boldiš V, Ondriska F, Köppl J, Brenner M, Nohýnková E, Perglerová A, Minichová L, Steinhűbel J. First detection of *Naegleria fowleri* in Slovakia associated with a fatal paediatric case of primary amoebic meningoencephalitis. Ann Agric Environ Med. doi:10.26444/aaem/242517

Abstract

Introduction. Primary amoebic meningoencephalitis (PAM) is a rare and fatal infection of the central nervous system caused by the free-living amoeba *Naegleria fowleri*.

Case Report. The report details the first fatal paediatric case of PAM detected in Slovakia. Following swimming lessons at a thermal pool in Štúrovo, an 11-year-old boy developed headache, fatigue, vomiting, and photophobia. On 13 June 2025, he was admitted to the Paediatric Intensive Care Unit with disturbances of consciousness, fever up to 40 °C, and petechiae. Parasitological examination confirmed *N. fowleri* infection.

Results and Conclusions. Diagnosis was confirmed by microscopy, Giemsa staining, culture, flagellation testing, scanning electron microscopy, and PCR. Despite treatment, MRI revealed acute cerebral ischemia and malignant brain oedema. The patient died four days after admission. PAM remains associated with high mortality, and early diagnosis is critical for patient outcome.

Key words

Naegleria fowleri, primary amoebic meningoencephalitis, free-living amoeba

INTRODUCTION

Naegleria fowleri is a free-living thermophilic protozoan, a microorganism that has been isolated from warm freshwater environments, including geothermal recreational waters and thermally impacted aquatic systems [1, 2]. Among the known species of the genus *Naegleria*, it is the only recognized human pathogen. It causes primary amoebic meningoencephalitis (PAM), an acute and fulminant disease of the central nervous system with a mortality rate exceeding 97%.

Human infection occurs when contaminated water enters the nasal cavity, most frequently during recreational water activities or through the use of non-sterile water for nasal irrigation. Trophozoites penetrate the olfactory epithelium and migrate through the cribriform plate along the olfactory nerve into the brain. The incubation period is typically 1–9 days. The clinical course begins with fever, headache, nausea, and vomiting, progressing rapidly to neck stiffness, seizures, coma, and death due to massive cerebral oedema [3].

Diagnosis relies on microscopic identification of trophozoites in fresh cerebrospinal fluid (CSF), *in vitro* culture, and PCR-based detection [4]. Computed tomography (CT) and magnetic resonance imaging (MRI) are useful for identifying diffuse cerebral oedema and focal lesions. Treatment consists of amphotericin B in combination with other drugs, most commonly rifampin, fluconazole, azithromycin, and miltefosine [5]. The extremely high mortality associated with PAM is related to its fulminant progression and frequent diagnostic delay; the few reported survivors highlight the importance of early recognition and prompt initiation of combination therapy [6].

The first documented case of PAM occurred in Australia in 1961 and was subsequently reported by Fowler and Carter in 1965; since then, several hundred cases have been reported worldwide [7, 8]. In Central Europe, PAM has particular historical relevance because of a major outbreak associated with an indoor swimming pool in Ústí nad Labem in the former Czechoslovakia in the 1960s, resulting in 16 deaths among young people [9, 10]. *Naegleria fowleri* has also been detected in anthropogenic warm-water environments in the Czech Republic, including cooling circuits of industrial and power plants [11]. Published information on the occurrence and distribution of *N. fowleri* and other *Naegleria* species in Slovakia is limited, and no human case of PAM had been documented in Slovakia prior to the present case.

✉ Address for correspondence: Vojtech Boldiš, Department of Parasitology, Medirex Ltd., Galvaniho 17/C, 82104, Bratislava, Slovak Republic
E-mail: vojtech.boldis@medirex.sk

Received: 02.07.2026; accepted: 03.11.2026; first published: 25.11.2026

CASE REPORT

Clinical course. From 7–11 June 2025, a boy who was almost 12 years old experienced five days of fatigue, headaches, and anorexia. However, he felt relatively well and continued to attend school. On 12 June, he developed a severe headache, began vomiting, and developed photophobia. After being evaluated by a community paediatrician, he was referred to the Emergency Department, where neurological assessment, including a brain CT scan, revealed no abnormalities. He was subsequently discharged fully conscious. The following day, 13 June, he vomited repeatedly, bit his lips, became somnolent, and became progressively unresponsive. Due to the progressive impairment of consciousness, he was transferred to the Paediatric Intensive Care Unit (PICU). Upon admission, the patient had a fever of up to 40 °C and responded only to strong stimuli. His Glasgow Coma Scale (GCS) score, a clinical tool used to assess coma severity, based on eye, verbal, and motor responses, had dropped from 11 to 7.

Due to the patient's rapidly progressive clinical condition, high fever, and suspected life-threatening bacterial neuroinfection, an immediate course of empirical antibacterial therapy with cefotaxime, followed by vancomycin, was initiated upon admission. A subsequent lumbar puncture revealed turbid cerebrospinal fluid (CSF) under pressure. Analysis of the CSF showed decreased glucose concentration (1.37 mmol/L; reference range: 2.2–4.2 mmol/L) and increased protein levels (2.948 g/L; reference range: 0.20–0.45 g/L). The leukocyte count was 14.38 × 10^9/L (reference range: 3–5 × 10^6/L) with a predominance of neutrophil granulocytes.

Microscopic examination of the CSF revealed amoeboid cells morphologically suggestive of *Naegleria* trophozoites. Following communication of this finding, a recommended anti-PAM therapy was initiated with amphotericin B deoxycholate (1.0–1.5 mg/kg/day), azithromycin (10 mg/kg/day), and fluconazole (10 mg/kg/day), while further diagnostic confirmation was undertaken. Amphotericin B deoxycholate was administered as the first dose because it was the only formulation immediately available; from the second dose onwards, treatment was continued with intravenous liposomal amphotericin B. Nevertheless, the patient's condition rapidly deteriorated, with progressive impairment of consciousness. He developed polyuria and became completely unresponsive.

On 14 June, miltefosine (50 mg twice daily) was added to the treatment regimen. On the same day, MRI of the brain demonstrated global ischemia and malignant cerebral oedema (Fig. 1a, b, c). Elevated inflammatory markers and disturbances in water and electrolyte balance were noted. Analgosedation was discontinued on June 15.

Based on MRI findings and overall clinical status, brain death was declared on 16 June. The patient was disconnected from mechanical ventilation and died on 17 June 2025.

Identification of *Naegleria fowleri*. On 13 June, a fresh CSF sample from the patient was delivered to the laboratory. Evaluation of the sample for bacteria via Gram staining and cultivation yielded negative results. The sample was spun down at 500 x g for 10 min at room temperature. A wet mount was prepared from the sediment and examined immediately under a microscope to check for amoebae. Smears were prepared from the sediment and stained with Giemsa [12].

Microscopic examination of the wet mount revealed numerous leukocytes and several cells that moved and appeared morphologically similar to amoebic trophozoites of *N. fowleri* (Fig. 2a). The presence of the trophozoites was confirmed on Giemsa-stained smears (Fig. 2b, c). The laboratory communicated these initial results by telephone within 35 minutes of receiving the sample.

Meanwhile, a sample of fresh CSF sediment was inoculated onto a plate of 1.5% non-nutrient agar (NN) (Bacto Agar, Difco) overlaid with heat-killed *Escherichia coli* and incubated at 37 °C. The primary culture was established at the Department of Parasitology, Medirex Ltd., Bratislava, under the appropriate containment and protective measures for handling potentially infectious clinical material. The inoculated plate was examined microscopically daily for the presence of amoebae over a 10-day period. The transformation of trophozoites into flagellate stages was confirmed by the flagellation test [13]. This method differentiates the genus *Naegleria* from other pathogenic genera of free-living amoebae that cause CNS infections in humans [14].

Culture-based diagnosis on the NN agar plate was decisive for PAM confirmation. Within 24 hours, on 14 June, trophozoites had proliferated to cover nearly half of the agar plate (Fig. 2d).

A positive flagellation test performed on 15 June also supported the conclusion that the amoebic trophozoites on the plate were from the genus *Naegleria* (Fig. 2e, f). By 18 June,

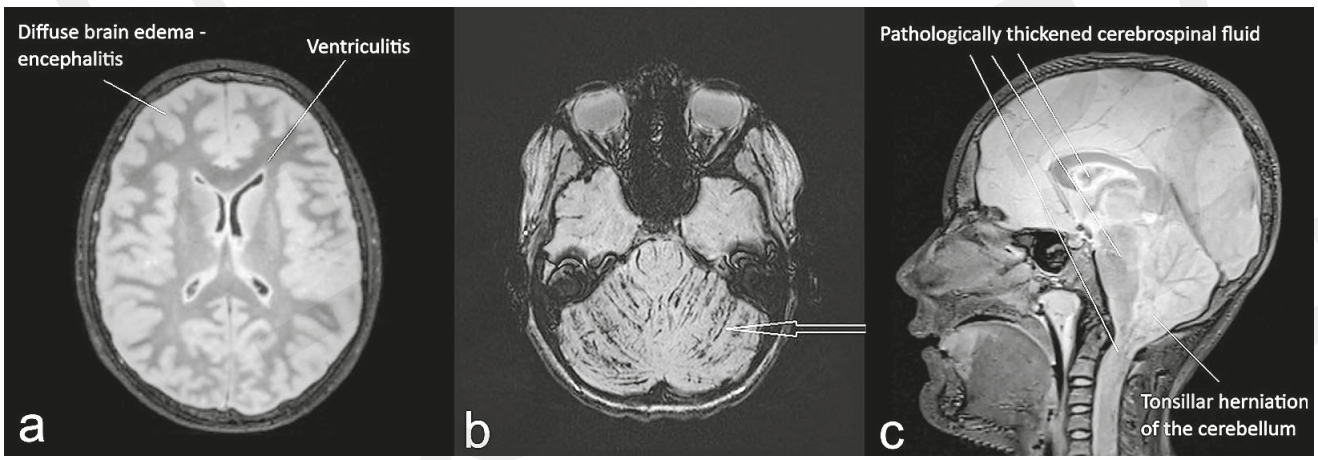

Figure 1. MRI findings – (a) diffuse cerebral oedema – encephalitis, cortical swelling, ventriculitis; (b) diffuse cerebellar subarachnoid haemorrhage (arrow); (c) FLAIR sequence showing cerebellar tonsillar herniation through the foramen magnum and pathologically thickened contents in intracranial and spinal CSF spaces

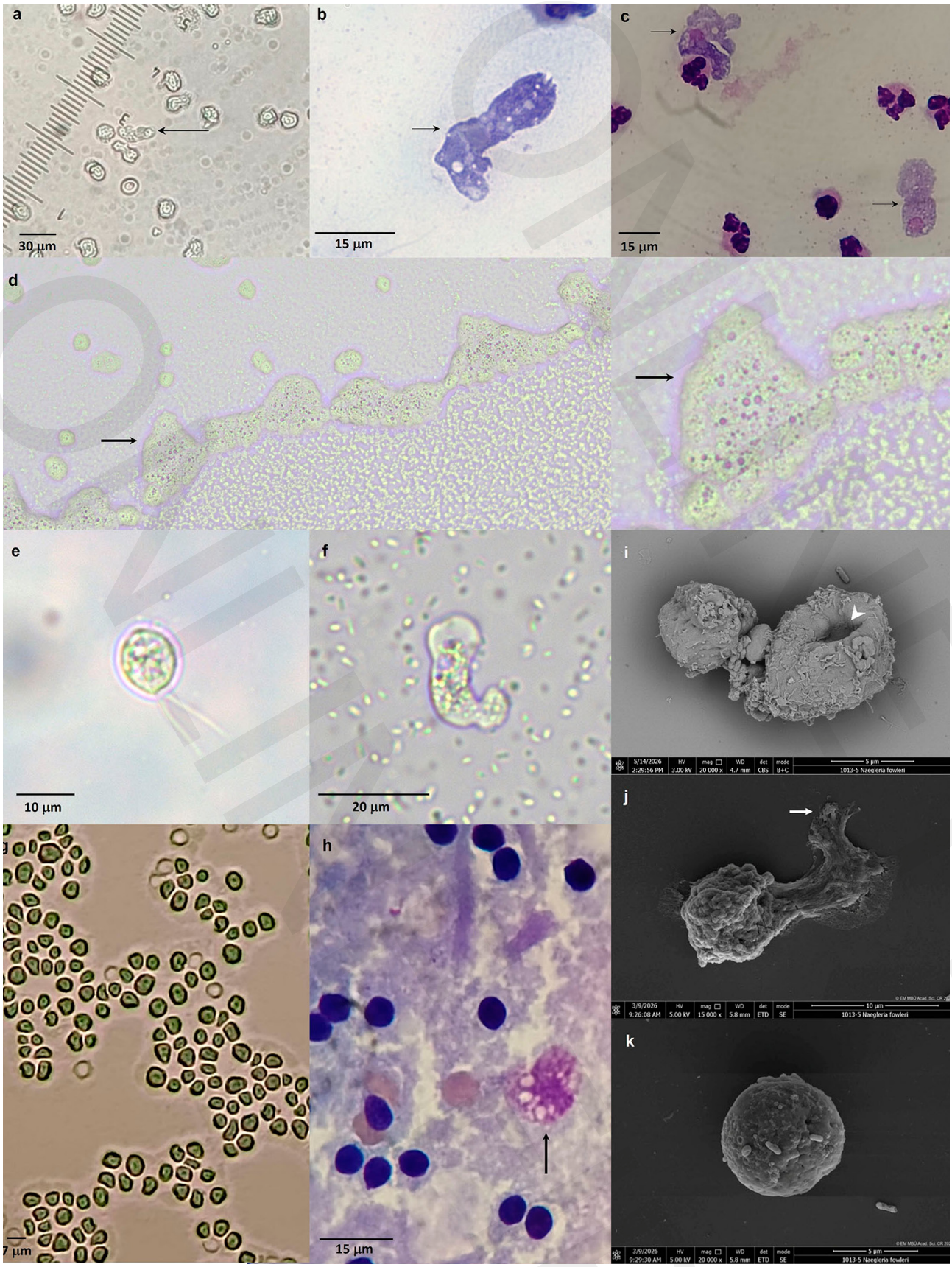

Figure 2. (a) PAM-associated trophozoites of *Naegleria fowleri* in CSF wet mount with visible lobopodia (arrow); (b, c) Giemsa-stained trophozoites in methanol-fixed smears (arrows); (d) a massive proliferation of trophozoites (arrow) in culture from patient CSF on NN agar (magnification 100×), detail showing dense trophozoite accumulation (arrow); (e) the flagellate stages of *N. fowleri* with two anterior flagella; (f) a motile trophozoite with lobopodial movement; (g) *N. fowleri* cysts formed after bacterial depletion on NN agar, showing thick walls and round to oval morphology; (h) a trophozoite in post-mortem brain tissue imprint smear stained with Giemsa (arrow); SEM micrographs showing (i) trophozoite clusters with visible amoebostome (arrowhead), (j) trophozoite extending a lobopodium (arrow), and (k) spherical cyst

round to oval *Naegleria* cysts were observed microscopically on agar plates (Fig. 2g).

The culture specimens were fixed in 2.5% glutaraldehyde in 0.1 M cacodylate buffer and processed for scanning electron microscopy (SEM), as described by Mácha et al. [15]. Imaging was performed using a FEI Nova NanoSEM (FEI, Brno, Czech Republic) at 5 kV (Fig. 2i, j, k). SEM revealed clustered trophozoites with visible amoebostomes, active lobopodia formation, and spherical cysts in the clinical isolate of *N. fowleri*.

During the autopsy on 18 June, brain tissue specimens were used to prepare imprint smears and inoculate agar plates. Microscopic examination of the Giemsa-stained smears confirmed the presence of amoebae (Fig. 2h); however, no amoebae from the necropsy specimen were grown *in vitro*.

To further confirm the PAM diagnosis, the viable clinical isolate was subsequently transferred under appropriate conditions to the Department of Medical Microbiology, First Faculty of Medicine, at Charles University in Prague, Czech Republic, where further handling and axenization were performed under Biosafety Level 3 (BSL-3) containment conditions. The isolate was axenized in BCS medium supplemented with penicillin [16] and designated as TTSL-25NF.

DNA was isolated from axenic cultures of the patient's strain (TTSL-25NF) and the control strain (HB1) of *N. fowleri* (ATCC 30174) using the Blood and Tissue QIA kit according to the manufacturer's protocol (Qiagen, Germany). The HB1 strain of *N. fowleri* was originally isolated from CSF of a patient with PAM in the USA in 1968 [17] and deposited in the ATCC. This strain was obtained by courtesy of R. Šuťák at BIOCEV in Prague.

Two ITS-based nested PCR assays were performed: a *Naegleria* genus-specific assay using ITS_N primers and an *N. fowleri* species-specific assay using ITS_NF primers [18–20]. Additionally, nested PCR targeting the Mp2CL5 gene, which encodes an *N. fowleri* membrane antigen, was performed. The Mp2CL5 target was demonstrated to be specific for *N. fowleri* when tested against other *Naegleria* and *Acanthamoeba* species, supporting its use for species-specific molecular detection [21]. These protocols have been widely used to detect this pathogenic amoeba in clinical samples [22, 23, 24]. Primary and secondary PCR reactions were performed for each ITS region and Mp2CL5, using outer and inner primer pairs under the conditions outlined in Tables 1, 2 and 3. The resulting PCR amplicons (Fig. 3) were Sanger sequenced at the OMICS genomics laboratory (BIOCEV, Prague, Czech Republic) and used for a BLAST analysis to compare the sequences with those of *N. fowleri* deposited in the NCBI database. The ITS_N and ITS_NF fragment sequences (approximately 410 and 310 bp, respectively) were 100% identical to the ITS1 nucleotide sequences of *N. fowleri* isolates SI1 (GenBank Accession No. ON197491) and NF_M2 (GenBank Accession No. PV151534). The Mp2CL5 gene sequence was rather short (approx. 110 bp). BLAST analysis revealed a match with the *N. fowleri* membrane protein (Mp2CL5) mRNA (AY049749.1), complete cds.

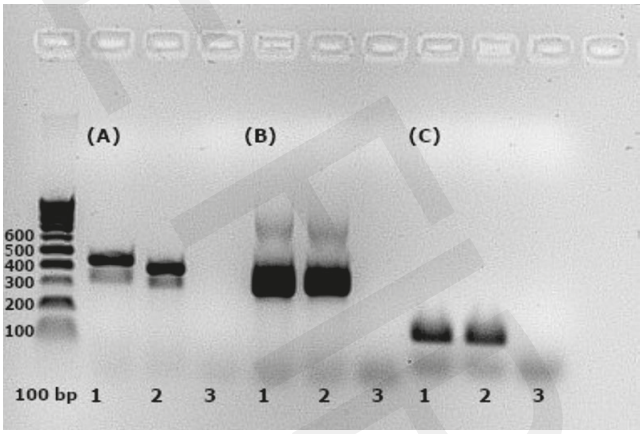

Figure 3. Gel electrophoresis of PCR products using primers specific for the Naegleria genus (A), N. fowleri (B), and Mp2CL5 positive controls (C). Lane 1: control strain HB1; lane 2: patient isolate TTSL-25NF; lane 3: negative control. A 100 bp DNA ladder served as the molecular marker

Table 1. Amplified regions and sequences of primers used in the nested PCR. Annealing temperatures and expected product sizes are shown

Amplified region		Primer Sequence 5′→3′	Annealing temperature	Product size (bp)	Source
ITS_ Naegleria	Fw1	GAACCTGCGTAGGGATCATTT	55 °C	311–500	[18,19]
	Rv1	TTTCTTTTCCTCCCCTTATTA			
	Fw2	AACCTGCGTAGGGATCATTT	55 °C	~410	[20]
	Rv2	TTTCCTCCCCTTATTAATAT			
ITS_N. fowleri	Fw1	GAACCTGCGTAGGGATCATTT	53 °C	311–500	[18,19]
	Rv1	TTTCTTTTCCTCCCCTTATTA			
	Fw2	GTGAAAACCTTTTTTCCATTTACA	55 °C	~310	[18,19]
	Rv2	AAATAAAAGATTGACCATTTGAAA			
Mp2CL5 gene	Fw1	TCTAGAGATCCAACCAATGG	65 °C	166	[21]
	Rv1	ATTCTATTCACTCCACAATCC			
	Fw2	GTACATTGTTTTTATTAATTTCC	55 °C	110	[21]
	Rv2	GTCTTTGTGAAAACATCACC			

Table 2. Components used for preparation of the PCR mastermix with a total volume of 25 µL. For each amplified region, the appropriate pair of primers was used (Tab. 1)

Component	Final concentration	Manufacturer
Taq DNA polymerase, 5U/µl	0.5U/reaction	Qiagen, Germany
10x Taq Buffer with $(NH_4)_2SO_4$	1x	Thermo Fisher Scientific, USA
25mM $MgCl_2$	2 mM	Thermo Fisher Scientific, USA
Dimethyl sulfoxide	5 %	Sigma Aldrich, Germany
10mM dNTP Mix PCR grade	200 µM	Qiagen, Germany
10µM forward primer (Tab. 1 – Fw)	0.25 µM	Integrated DNA Tech., USA
10µM reverse primer (Tab. – Rv)	0.25 µM	Integrated DNA Tech., USA
Template DNA, 2 µL	–	–
Nuclease-free H_2O (PCR grade), up to 25 µL	–	Sigma Aldrich, Germany

Table 3. Amplification conditions used in the nested PCR. Annealing temperature is specific for each pair of primers (Tab. 1)

Step	Temperature	Time [min]	
Denaturation	94 °C	5:00	
Denaturation	94 °C	0:30	
Annealing	Table 1	0:30	repeated 35x
Extension	72 °C	1:00	
Extension	72 °C	7:00	

Epidemiological investigations. Epidemiological surveillance revealed that, shortly before the onset of non-specific symptoms, the boy had attended a swimming course at the Vadaš Thermal Resort in Štúrovo from 2–6 June 2025, as part of a boarding school programme. The facility comprises an outdoor thermal swimming complex supplied with naturally occurring geothermal groundwater, with colder groundwater used to regulate pool temperatures. The outdoor pools have different operating temperatures depending on their purpose, ranging from approximately 28 °C in the swimming pool to 30–40 °C in recreational and relaxation pools. According to the subsequent epidemiological investigation, the boy had used all the pools, including the water slides, but not the seated whirlpool.

A public health investigation performed on 14 June 2025, documented inadequate disinfection, with free chlorine concentrations as low as 0.05–0.12 mg/L in several pools.

DISCUSSION

Due to the short incubation period and rapidly fulminant course of the disease, early detection of infection is critical for patient survival. For the presented patient, the estimated latency period from probable exposure in the thermal pool to the onset of symptoms (headache, vomiting, and photophobia) was 6–11 days. This is consistent with the findings of multiple studies that reported incubation periods of 1–7 days and extremely rapid progression [14]. During the initial clinical phase, the patient experienced fatigue, headache, and anorexia, followed on 12 June by severe headache, vomiting, and photophobia. Neurological examination revealed no focal deficits, and computed tomography (CT) showed no abnormalities; however, signs of neuromuscular irritability and neurasthenia were observed. Laboratory findings, including turbid CSF and neutrophilic pleocytosis, were consistent with purulent meningitis.

Rapid deterioration of consciousness within hours, global cerebral ischemia, and malignant cerebral oedema reflect the aggressive pathogenicity of *N. fowleri* and host neuroinflammatory responses [25]. Differences in virulence among *N. fowleri* strains have been associated with the expression of specific virulence factors that may contribute to disease progression [26]. Although the virulence characteristics of the isolate from the presented patient were not specifically investigated, strain-related virulence may have contributed to the rapidly progressive clinical course observed in this case.

The present case illustrates the diagnostic challenge of PAM during the early clinical phase, when symptoms may be nonspecific and initial neuroimaging may be unremarkable. A detailed history of recent exposure to warm recreational water may therefore represent an important diagnostic clue. In such patients, early suspicion of PAM may prompt rapid examination of fresh CSF and specific molecular testing for *N. fowleri*.

The therapeutic strategy employed amphotericin B, azithromycin, fluconazole, and miltefosine, an approach that aligns with current recommendations for aggressive combination therapy in PAM [27]. Nevertheless, mortality remains extremely high [28].

The main epidemiological risk factor is exposure to warm freshwater [1]. This case contributes to data on the occurrence of *N. fowleri* in Central Europe and raises awareness of the risks associated with bathing in thermal pools. A subsequent public health investigation performed on 14 June 2025, documented inadequate disinfection, with free chlorine concentrations of 0.05–0.12 mg/L in several pools. However, these measurements were obtained after the patient's exposure period (2–6 June 2025) and therefore may not reflect the chlorine concentrations at the time of exposure. Interestingly, the historical PAM outbreak in Ústí nad Labem, former Czechoslovakia, which resulted in 16 fatal cases between 1962 and 1965, was also associated with a swimming pool environment. Subsequent investigations identified a water-filled cavity behind a damaged pool wall, where the water temperature reached approximately 27–30 °C and the amoebae were relatively protected from disinfection [9, 10]. In comparison, the outdoor pools associated with the present case operated at temperatures ranging from approximately 28 °C in the swimming pool to 30–40 °C in recreational and relaxation pools. Direct comparison of chlorine concentrations between the two events is limited by the absence of contemporaneous chlorine measurements during the exposure period in the present case.

There have been a few documented cases of survival in patients who received an early diagnosis of PAM and were treated with aggressive combination therapy [28, 29]. The surviving case of a 14-year-old boy in Kerala, India, emphasizes the critical role of early clinical suspicion, rapid diagnosis, and immediate initiation of aggressive multi-drug treatment, including miltefosine [29]. In the presented case, the microscopic examination yielded a result within 35 minutes of receiving the CSF sample. The sample was taken on the same day that severe symptoms developed. However, PAM was not suspected during the earlier clinical phase, when the initial cranial CT findings were unremarkable. This highlights the difficulty of early recognition of PAM before rapid neurological deterioration occurs.

Preventive measures should include avoiding diving or submerging the head in warm freshwater and minimizing the entry of water into the nose, for example by using nose clips during water-related activities. In addition, when organizing swimming courses for children, consideration should be given to choosing appropriately maintained and disinfected swimming facilities with cooler water, rather than warm geothermal pools, particularly when activities involve repeated submersion of the head.

CONCLUSION

This report documents the first confirmed case of PAM caused by *N. fowleri* in Slovakia. Rapid microscopic examination of CSF enabled early laboratory suspicion, subsequently confirmed by culture and PCR. However, despite aggressive combination therapy, the infection resulted in fatal cerebral oedema.

The case emphasizes that PAM should be considered a medical emergency requiring immediate empirical anti-amoebic therapy and rapid laboratory investigation in patients with acute meningoencephalitis following exposure to warm recreational water.

Consent for publication. Written informed consent was obtained from the legal guardian(s) of the patient for the publication of this case report and any accompanying images.

Clinical trial number. Not applicable.

Disclosure. The author reports no conflicts of interest in this work.

Competing interests. The authors declare no competing interests.

REFERENCES

1. Moussa M, De Jonckheere JF, Guerlotté J, et al. Survey of Naegleria fowleri in geothermal recreational waters of Guadeloupe (French West Indies). PLoS One. 2013;8(1):e54414. doi:10.1371/journal.pone.0054414
2. De Jonckheere J, Van Dijck P, Van de Voorde H. The effect of thermal pollution on the distribution of Naegleria fowleri. J Hyg (Lond). 1975;75(1):7–13. doi:10.1017/S0022172400047021
3. Burqi AMK, Satti L, Mahboob S, et al. Successful treatment of confirmed Naegleria fowleri primary amebic meningoencephalitis. Emerg Infect Dis. 2024;30(4):803–805. https://doi.org/10.3201/eid3004.230979
4. Miller JM, Binnicker MJ, Campbell S, et al. Guide to utilization of the microbiology laboratory for diagnosis of infectious diseases: 2024 update by the Infectious Diseases Society of America (IDSA) and the American Society for Microbiology (ASM). Clin Infect Dis. 2024;ciae104. doi:10.1093/cid/ciae104
5. Rauf A, Rahiman FA, Poornima MV, et al. Early diagnosis and successful treatment of a child with confirmed primary amebic meningoencephalitis. Indian J Pediatr. 2025;92(4):446. https://doi.org/10.1007/s12098-025-05458-1
6. Hall AD, Kumar JE, Golba CE, et al. Primary amebic meningoencephalitis: a review of Naegleria fowleri and analysis of successfully treated cases. Parasitol Res. 2024;123(1):84. doi:10.1007/s00436-023-08094-w. PMID: 38182931
7. Fowler M, Carter RF. Acute pyogenic meningitis probably due to Acanthamoeba sp.: a preliminary report. Br Med J. 1965;2(5464):740–742. doi:10.1136/bmj.2.5464.734-a
8. Alanazi A, Younas S, Ejaz H, et al. Advancing the understanding of Naegleria fowleri: Global epidemiology, phylogenetic analysis, and strategies to combat a deadly pathogen. J Infect Public Health. 2025;18(4):102690. https://doi.org/10.1016/j.jiph.2025.102690
9. Červa L, Novák K. Amebic meningoencephalitis. 16 fatalities. Science 1968;160(3823):92.
10. Červa L, Novák K, Culbertson CG. An outbreak of acute, fatal amebic meningoencephalitis. Am J Epidemiol. 1968;88(3):436–444. doi:10.1093/oxfordjournals.aje.a120905
11. Červa L, Simanov L. Naegleria fowleri in cooling circuits of industrial and power plants in north Moravia. Folia Parasitologica. 1983;30(1):97–101. PMID:6862318
12. Ondriska F, Kaiglová A, Boldiš V. Selected chapters from general and special clinical parasitology and laboratory examination methods. 1st ed. Trnava: Vedap; 2019. (in Slovak)
13. Lares-Jiménez LF, Rodriguez-Anaya LZ, Alfaro-Sifuentes R, et al. Population dynamics of Naegleria fowleri genotype 2 in natural aquatic environments of Sonora, Mexico, throughout the year. Biotecnia. 2025;27:e2528. https://doi.org/10.18633/biotecnia.v27.2528
14. Güémez A, García E. Primary amoebic meningoencephalitis by Naegleria fowleri: pathogenesis and treatments. Biomolecules. 2021;11(9):1320. doi:10.3390/biom11091320
15. Mácha H, Marešová H, Juříková T, et al. Killing effect of Bacillus velezensis FZB42 on a Xanthomonas campestris pv. Campestris (Xcc) strain newly isolated from cabbage Brassica oleracea convar. Capitata (L.): a metabolomic study. Microorganisms. 2021;9. https://doi.org/10.3390/microorganisms9071410
16. Měřínská T, Scholtz V, Khun J, et al. Inactivation of Acanthamoeba cysts in suspension and on contaminated contact lenses using non-thermal plasma. Microorganisms. 2021;9(9):1879. doi:10.3390/microorganisms9091879. PMID: 34576774; PMCID: PMC8465664
17. Culbertson CG, Ensminger PW, Overton WM. Pathogenic Naegleria sp.- study of a strain isolated from human cerebrospinal fluid. J Protozool. 1968;15(2):353–363. doi:10.1111/j.1550-7408.1968.tb02136.x
18. Pélandakis M, Serre S, Pernin P. Analysis of the 5.8S rRNA gene and the internal transcribed spacers in Naegleria spp. and in N. fowleri. J Eukaryot Microbiol. 2000;47(2):116–121. doi:10.1111/j.1550-7408.2000.tb00020.x
19. Ithoi I, Ahmad AF, Nissapatorn V, et al. Detection of Naegleria species in environmental samples from Peninsular Malaysia. PLoS ONE. 2011;6(9):e24327. https://doi.org/10.1371/journal.pone.0024327
20. Gunarathna N, Amarasinghe A, Wijesundara S, et al. Isolation, molecular characterization and phylogeny of Naegleria species in water bodies of North-Western Province, Sri Lanka. PLoS ONE. 2021;16(3):e0248510. https://doi.org/10.1371/journal.pone.0248510
21. Réveiller FL, Cabanes PA, Marciano-Cabral F. Development of a nested PCR assay to detect the pathogenic free-living amoeba Naegleria fowleri. Parasitol Res. 2002;88(5):443–450. doi:10.1007/s00436-002-0591-x
22. Cogo PE, Scaglia M, Gatti S, et al. Fatal Naegleria fowleri meningoencephalitis, Italy. Emerg Infect Dis. 2004;10(10):1835–1837. doi:10.3201/eid1010.040273
23. Soontrapa P, Jitmuang A, Ruenchit P, et al. The first molecular genotyping of Naegleria fowleri causing primary amebic meningoencephalitis in Thailand with epidemiology and clinical case reviews. Front Cell Infect Microbiol. 2022;12:article 931546.
24. Zhang L, Wu M, Hu B, et al. Identification and molecular typing of Naegleria fowleri from a patient with primary amebic meningoencephalitis in China. Int J Infect Dis. 2018;72:28–33.
25. Ahmad Zamzuri M'I, Abd Majid FN, Mihat M, et al. Systematic review of brain-eating amoeba: A decade update. Int J Environ Res Public Health. 2023;20(4):3021. https://doi.org/10.3390/ijerph20043021
26. Rodríguez-Mera IB, Rojas-Hernández S, Barrón-Graciano KA, et al. Analysis of virulence factors in extracellular vesicles secreted by Naegleria fowleri. Parasitol Res. 2024;123(10):357. https://doi.org/10.1007/s00436-024-08378-9
27. Debnath A. Drug discovery for primary amebic meningoencephalitis: from screen to identification of leads. Expert Rev Anti Infect Ther. 2021;19(9):1099–1106. doi:10.1080/14787210.2021.1882302
28. Perumalsamy V, Sundaramoorthy R, Ganesan V, et al. Survival of primary amebic meningoencephalitis by Naegleria fowleri: First reported case from Tamil Nadu, South India. Trop Parasitol. 2020;10(2):150–152. doi:10.4103/tp.TP_34_19. PMID: 33747885; PMCID: PMC7951067
29. Qureshi I. India teen is rare survivor of brain-eating amoeba. BBC NEWS, 2024. Kerala: Teenager survives rare brain-eating amoeba disease. In: BBC [online]. 30.7.2024. https://www.bbc.com/news/articles/cy79w93l712o (access: 2026-07-05)

ONLINE FIRST