



Difficulties in management of ocular surface in the late phase of toxic epidermal necrolysis – a rare case report

Dominika Wróbel-Dudzińska^{1,A-F}✉, Agnieszka Ćwiklińska-Haszcz^{1,A-B,E},
Ewa Kosior-Jarecka^{1,A-B,E}, Tomasz Żarnowski^{1,E-F}

¹ Department of Diagnostics and Microsurgery of Glaucoma, Medical University, Lublin, Poland

A – Research concept and design, B – Collection and/or assembly of data, C – Data analysis and interpretation, D – Writing the article, E – Critical revision of the article, F – Final approval of the article

Wróbel-Dudzińska D, Ćwiklińska-Haszcz A, Kosior-Jarecka E, Żarnowski T. Difficulties in management of ocular surface in the late phase of toxic epidermal necrolysis- a rare case report. *Ann Agric Environ Med*. doi: 10.26444/aaem/202806

Abstract

Introduction. The report discusses the management of ocular surface complications in the late phase of toxic epidermal necrolysis, with an emphasis on strategies to mitigate these debilitating consequences.

Case Report. A 75-year-old male presented with severe ocular complications, including visual acuity loss, pain, and tearing in the right eye (RE), stemming from chronic-phase Toxic Epidermal Necrolysis (TEN) triggered by allopurinol two years previously. Initial examination revealed cicatricial entropion in both eyes (BE), with the right eye (RE) exhibiting conjunctival cicatrization, symblepharon, corneal neovascularization, and a 3 mm corneal perforation. The patient underwent a combination of surgical and medical interventions, including fornix reconstruction, customized mini-keratoplasty, amniotic membrane transplantation, and partial tarsorrhaphy. Post-operative treatment included topical dexamethasone, tobramycin, cyclosporine, artificial tears, and oral prednisone. Despite ongoing treatment, including the addition of platelet-rich plasma, the right eye's best-corrected visual acuity (BCVA) remained at light perception, with persistent corneal haziness, neovascularization, progressive conjunctival cicatrization, and keratinization.

Conclusions. This case highlights the significant challenges of managing late-phase ocular complications in SJS/TEN, emphasizing the need for a multidisciplinary approach and aggressive intervention to preserve ocular structure and function.

Key words

Stevens-Johnson syndrome, Toxic epidermal necrolysis, keratoplasty, amniotic membrane

INTRODUCTION

Toxic epidermal necrolysis (TEN), also known as Lyell syndrome, is a severe and potentially life-threatening form of Stevens-Johnson syndrome (SJS). This acute inflammatory condition involves vesiculobullous reactions affecting the skin and at least two mucous membranes. The classification of SJS/TEN is determined by the extent of skin involvement: SJS if less than 10%, SJS/TEN overlap for 10% – 30%, and TEN if more than 30% of the skin is affected [1].

The reported incidence of SJS ranges from 1.2 – 6 cases per million patient-years, while TEN occurs in 0.4 – 1.2 cases per million patient-years. Incidence increases with age, and individuals with human immunodeficiency virus (HIV) infection are at higher risk. Mortality rates are significant, with 1% – 10% for SJS and 25% – 40% for TEN, as reported by Jain et al. [2, 3].

TEN is caused by a delayed type III hypersensitivity reaction, often triggered by drug exposure. A wide range of medications have been implicated, including antibiotics (e.g., sulfonamides, penicillins, and trimethoprim), allopurinol, analgesics (such as paracetamol/acetaminophen), nevirapine (used in HIV therapy), cold remedies (Ibuprofen, diclofenac, paracetamol/acetaminophen), and anti-convulsants (lamotrigine, carbamazepine, phenytoin, phenobarbitone).

Other triggers include infections (e.g., *Herpes simplex*, *Mycoplasma pneumoniae*, *Coxsackie virus*, and *Streptococcus*) and certain cancers. However, in many cases, the causative factor may remain unidentified due to the delayed onset of symptoms, which can take weeks to appear.

TEN typically progresses through an acute phase followed by a chronic phase. During the acute stage, which lasts 2 – 6 weeks, intensive medical care, including ophthalmologic management, is critical [2]. Initial symptoms include extensive sloughing of skin and mucosal surfaces. The most common ocular manifestation is non-specific bilateral diffuse conjunctivitis, occurring in 15% – 75% of cases, and may be accompanied by pseudomembranes, hyperaemia, ocular surface sloughing, tarsal conjunctival involvement, and lid margin erosion. Corneal complications include epithelial defects, pannus formation, and, in severe cases, corneal ulceration. Symblepharon may also develop.

The chronic phase, unfortunately, can persist for the patient's lifetime. Late-stage ocular complications include eyelid abnormalities, such as cicatricial entropion, ectropion, trichiasis, metaplastic lashes, and ankyloblepharon. Keratinization of the conjunctiva and lid margin, sometimes with abrasive plaque formation, is common. Additional findings include conjunctival cicatrization, fornical shortening, and symblepharon. These structural changes can lead to keratopathy characterized by corneal scarring, vascularization, keratinization, punctate erosion, epithelial defects, and, in severe cases, corneal perforation. Dry eye syndrome may result from fibrosis of the lacrimal gland

✉ Address for correspondence: Dominika Wróbel-Dudzińska, Department of Diagnostics and Microsurgery of Glaucoma, Medical University, Lublin, Poland
E-mail: dwrobeldudzinska@interia.pl

Received: 18.12.2024; accepted: 10.03.2025; first published: 28.03.2025

ductules and conjunctival metaplasia with goblet cell loss, causing tear film instability.

According to the literature, the first reported case of allopurinol-induced toxic epidermal necrolysis (TEN) with ocular manifestations was published by Bennett in 1977. The case involved a 54-year-old man undergoing allopurinol therapy for hyperuricaemia who developed symptoms of TEN after three weeks of treatment. His ocular complications included symblepharon, pseudomembranous conjunctivitis with ulcerative lesions on the eyelids and conjunctiva, and punctate corneal staining leading to corneal epithelial defects. Despite treatment with topical antibiotics (gentamycin ointment) and artificial tears, punctate staining and dry eye symptoms persisted for 14 months. He later developed bilateral corneal ulcers requiring partial conjunctival flaps in both eyes, with a final visual acuity of 20/40 in both eyes [4].

Subsequently, Lee described two cases of allopurinol-induced TEN presenting with only mild conjunctival hyperaemia. Treatment included topical and systemic steroids, topical antibiotics, and preservative-free artificial tears. Notably, neither patient developed severe chronic ocular complications. However, one had bilateral persistent epithelial defects which, upon healing, resulted in central corneal haze [5]. Another report by Hoyer noted that despite the patient's severe systemic condition, ophthalmic findings were limited to conjunctival lesions and erythema, which resolved quickly with anti-infective and lubricating treatments [6].

Given the limited number of studies in the literature and the generally mild ophthalmic course observed in these cases, the aim of the current report is to contribute the authors' clinical experience to this discussion.

According to the best of the authors' knowledge, this is the first Polish report presenting the management of ocular surface complications during the late phase of TEN, focusing on strategies to address these debilitating outcomes.

CASE REPORT

A 75-year-old male presented to the hospital's emergency department with complaints of visual acuity loss, severe pain, and tearing in the right eye (RE). Best-corrected visual acuity (BCVA) was reduced to light perception in the RE and 0.3 (uncorrected, decimal scale) in the left eye (LE).

Slit-lamp examination revealed cicatricial entropion in both eyes (BE). The RE exhibited keratinization of the conjunctiva and lid margin, meibomian gland dysfunction (MGD), conjunctival cicatrization with forniceal shortening, symblepharon, corneal neovascularization, and a 3 mm corneal perforation with spontaneous Seidel positivity (Fig. 1). In contrast, the LE showed entropion with trichiasis, a transparent cornea with fluorescein staining, normal anterior chamber depth, and pseudophakia (Fig. 1).

Anterior segment optical coherence tomography (OCT) of the RE revealed the absence of the anterior chamber and iris prolapse at the site of the corneal perforation (Fig. 2). B-scan ultrasonography showed an attached retina in the RE.

Medical history was significant for Stevens-Johnson Syndrome (SJS)/Toxic Epidermal Necrolysis (TEN) triggered by allopurinol 2 years previously, which required treatment in the Dermatology and Anesthesiology Departments, including plasmapheresis. The patient also had a history of hypertension, type II diabetes mellitus, and hyperlipidaemia.

Previous ophthalmologic interventions included panretinal photocoagulation for diabetic retinopathy in both eyes, cataract surgery in the LE, Wiess procedure for eyelid correction in BE, and amniotic membrane transplantation with electroepilation in BE.

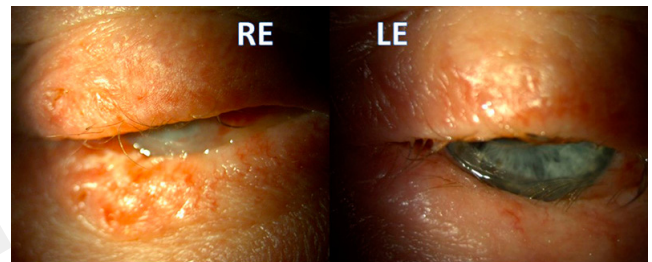


Figure 1. Cicatricial entropion in both eyes, keratinization of the lid margin, meibomian gland dysfunction (MGD), trichiasis. RE – symblepharon, keratinization of the conjunctiva, corneal opacity and neovascularization. LE – transparent cornea

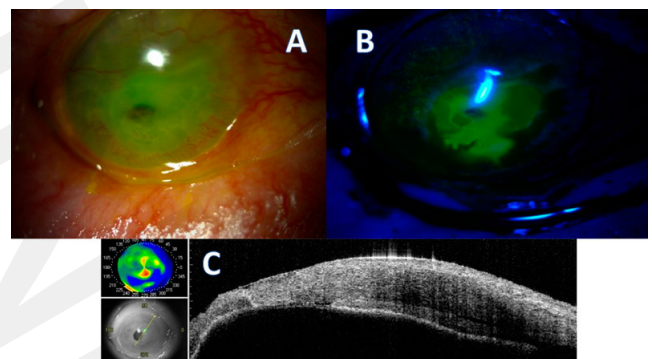


Figure 2 A-B: slit lamp examination – corneal opacity and neovascularization with perforation and Seidel positivity in cobalt filter; C: AS-OCT of RE – corneal perforation with iris prolapse and lack of the anterior chamber

Based on the patient's condition, we proceeded with eyelid massage, fornix reconstruction through plastic surgery, customized mini-keratoplasty at the site of perforation, amniotic membrane transplantation to cover the entire cornea and transplant, and partial temporal tarsorrhaphy (Fig. 3). The prescribed treatment regimen included dexamethasone eye drops 5 times a day, tobramycin eye drops 5 times a day, artificial tears 5 times a day, cyclosporine 0.05% eye drops twice daily, and oral prednisone (Encorton) at a dosage of 60 mg daily.

After 3 weeks, the patient developed skin scaling and mucopurulent conjunctivitis. As a result, it was decided to remove all sutures from the eyelids. The BCVA remained at light perception in the right eye (RE) and 0.3 in the left eye (LE). Slit lamp examination revealed signs of meibomian gland dysfunction (MGD), entropion, symblepharon, remnants of the amniotic membrane, a non-transparent corneal mini-graft, and a shallow anterior chamber observed in AS-OCT (Fig. 4). Platelet-rich plasma was added to the existing treatment regimen.

At the follow-up visit 5 weeks later, the BCVA remained unchanged. In the right eye, the amniotic membrane was no longer present, the corneal graft appeared hazy, and the patient's cornea exhibited neovascularization. Additionally, there was progressive cicatrization and keratinization of the conjunctiva and eyelid (Fig. 5).

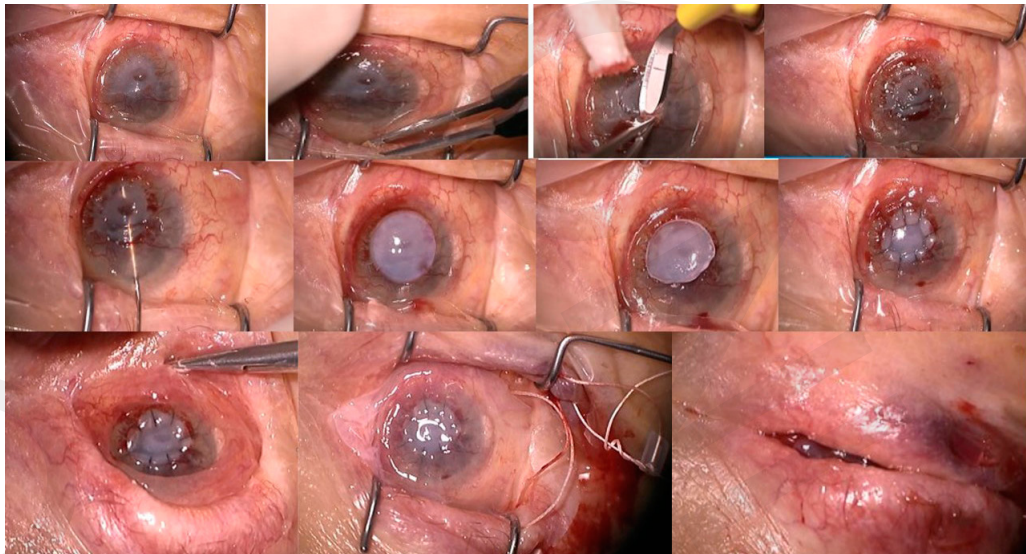


Figure 3. Stages in the reconstruction surgical technique. Eyelid hygiene with massage, and conjunctival sac irrigation, fornix reconstruction, reconstruction of the anterior chamber, customized mini-keratoplasty sutured at the perforation site, amniotic membrane transplantation to cover the entire ocular surface from the upper lid margin to the lower lid margin, and partial temporal tarsorrhaphy

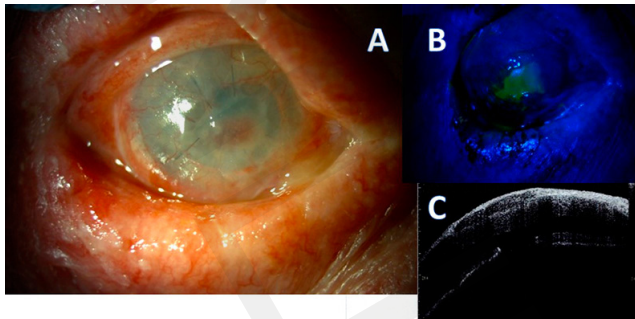


Figure 4 A, B. Slit lamp examination: entropion, symblepharon, remnants of the amniotic membrane and a non-transparent corneal mini-graft with epithelial defect, C AS-OCT cornea covered by the amniotic membrane remnants, shallow anterior chamber

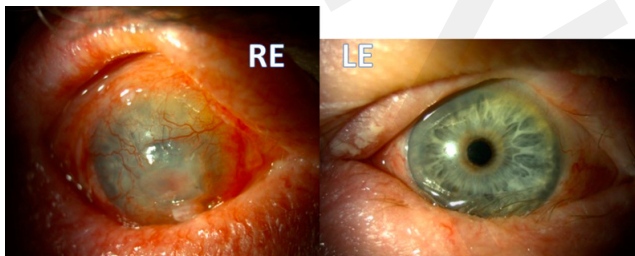


Figure 5. RE keratinization of the lid margin, corneal neovascularization and non-transparent cornea B LE progressive cicatrization and keratinization of the lid margin, and conjunctiva, trichiasis

DISCUSSION

The management of TEN is complex, requiring a multidisciplinary approach that extends beyond ophthalmologists to include other specialists. During the acute phase, ophthalmologic care should prioritize the suppression of ocular surface inflammation and the prevention of secondary complications. Studies recommend the use of systemic and topical corticosteroids along with amniotic membrane transplantation (AMT) [7, 8].

Literature suggests that performing AMT within the first few weeks of illness significantly reduces cicatricial damage, while its effectiveness diminishes as the disease progresses. Acute-phase management is critical, as severe and chronic ocular complications, which are often difficult to treat, can be prevented. Many experts emphasize that early application of the amniotic membrane increases the likelihood of minimizing inflammation and scarring [8, 9].

In the current case, the patient presented during the chronic phase of TEN, precluding intervention during the acute phase. Due to corneal perforation, customized mini-penetrating keratoplasty was performed combined with AMT, anticipating a limited long-term prognosis. Immunosuppressive therapy was administered to support transplant survival.

Additional approaches and techniques. The literature highlights alternative treatments for TEN-related complications. Some authors report success using subconjunctival triamcinolone injections combined with a symblepharon ring and Prokera® [10]. This bedside approach protects the cornea from the abrasive effects of scarred eyelid surfaces but does not shield the lid margins or meibomian glands, often rendering it insufficient.

For cases with poor corneal healing, keratoprosthesis options, such as the Boston Keratoprosthesis (KPro) or osteo-odonto keratoprosthesis (OOKP), have been employed [11, 12]. However, these procedures carry a higher risk of complications, including prosthesis extrusion, aqueous leaks, progressive glaucoma, retroprosthetic membranes, eyelid cellulitis, retinal detachment, and endophthalmitis. Additionally, both Type 2 KPro and OOKP are complex procedures available in only a few specialized centres globally.

Modern therapeutic strategies include keratolimbic allograft, cultivated human limbal epithelium, and serum-derived autologous cultivated oral epithelium transplantation. Literature suggests better outcomes with penetrating keratoplasty performed months after keratolimbic allograft. While short-term outcomes for Stevens-Johnson Syndrome (SJS)/TEN patients treated with these techniques

are promising, the long-term stability of the epithelial surface remains uncertain [13, 14]. Adjunctive treatments, such as topical transretinoic acid to reverse conjunctival transdifferentiation and topical/systemic vitamin A, may also support ocular surface healing [15].

In the presented case, despite the best efforts to address the chronic phase complications, the advanced nature of the disease presented significant challenges.

CONCLUSIONS

The involvement of an ophthalmologist skilled in the evaluation and management of TEN during the acute phase is essential. Basic measures, such as sweeping the fornices and applying lubricants, are inadequate for patients with extensive ocular surface sloughing. Prompt recognition of the severity of the condition and timely initiation of AMT are crucial. Early application of AMT during the acute phase has demonstrated significant potential in preventing the devastating ocular scarring characteristic of the chronic phase. Although the treatment of chronic-phase TEN remains challenging and prone to failure; preventing scarring during the acute phase is vital for improving long-term outcomes.

This case highlights the significant challenges in managing late-phase ocular complications in SJS/TEN, and emphasizes the need for a multi-disciplinary approach and aggressive intervention to preserve ocular structure and function.

Declaration of conflicting interest

The author(s) declared no potential conflicts of interest with respect to the research, authorship, and/or publication of this article.

Patient consent

Written informed consent was obtained from the patient for publication of the clinical details and clinical images.

REFERENCES

- Gregory DG. New Grading System and Treatment Guidelines for the Acute Ocular Manifestations of Stevens-Johnson Syndrome. *Ophthalmol.* 2016 Aug;123(8):1653–1658. doi:10.1016/j.ophtha.2016.04.041. Epub 2016 Jun 11. PMID:27297404
- Jain R, Sharma N, Basu S, Iyer G, Ueta M, Sotozono C, et al. Stevens-Johnson syndrome: The role of an ophthalmologist. *Surv Ophthalmol.* 2016 Jul-Aug;61(4):369–99. doi:10.1016/j.survophthal.2016.01.004. Epub 2016 Jan 30. PMID:26829569.
- Kojima M, Mieno H, Ueta M, Nakata M, Teramukai S, Sunaga Y, et al. Improvement of the Ocular Prognosis of Stevens-Johnson Syndrome and Toxic Epidermal Necrolysis: A National Survey in Japan. *Am J Ophthalmol.* 2024 Nov;267:50–60. doi:10.1016/j.ajo.2024.05.011. Epub 2024 May 24. PMID:38795750.
- Bennett TO, Sugar J, Sahgal S. Ocular manifestations of toxic epidermal necrolysis associated with allopurinol use. *Arch Ophthalmol.* 1977 Aug;95(8):1362–4. doi:10.1001/archophth.1977.04450080072005. PMID:889509
- Lee HS, Ueta M, Kim MK, Seo KY, Sotozono C, Kinoshita S, Yoon KC. Analysis of Ocular Manifestation and Genetic Association of Allopurinol-Induced Stevens-Johnson Syndrome and Toxic Epidermal Necrolysis in South Korea. *Cornea.* 2016 Feb;35(2):199–204. doi:10.1097/ICO.0000000000000708. PMID:26655481
- Hoyer D, Atti C, Nuding S, Vogt A, Sedding DG, Schott A. Toxic Epidermal Necrolysis Caused by Allopurinol: A Serious but Still Underestimated Adverse Reaction. *Am J Case Rep.* 2021 Oct 11;22:e932921. doi:10.12659/AJCR.932921. PMID:34634004; PMCID:PMC8522529
- Mieno H, Ueta M, Kinoshita F, Teramukai S, Kinoshita S, Sotozono C. Corticosteroid Pulse Therapy for Stevens-Johnson Syndrome and Toxic Epidermal Necrolysis Patients With Acute Ocular Involvement. *Am J Ophthalmol.* 2021 Nov;231:194–199. doi:10.1016/j.ajo.2021.06.015. Epub 2021 Jun 29. PMID:34214456
- Rashad R, Kwan JT, Shanbhag SS, Ngoyutagon P, Saeed M, Tahboub MA, et al. Long-term outcomes of glued (sutureless) amniotic membrane transplantation in acute Stevens-Johnson syndrome/toxic epidermal necrolysis: a comparative study. *Br J Ophthalmol.* 2024 Oct 22;108(11):1508–1513. doi:10.1136/bjo-2023-324076. PMID:38490716
- Sharma S, Singh S, Basu S, Shanbhag SS. Chronic Ocular Sequelae and Subsequent Surgical Interventions in Stevens-Johnson Syndrome After Amniotic Membrane Transplantation. *Cornea.* 2022 May 1;41(5):632–634. doi:10.1097/ICO.0000000000002816. PMID:34294633
- Mahmood AH, Alharbi AS, Almanea BA, Alsaati AF. Sutureless Amniotic Membrane (ProKera®) and Intravenous Immunoglobulin in the Management of Ocular Complications of Stevens-Johnson Syndrome-Toxic Epidermal Necrolysis Overlap. *Cureus.* 2021 Aug 8;13(8):e16989. doi:10.7759/cureus.16989. PMID:34540392; PMCID:PMC8422256
- Bonneau S, Tong CM, Yang Y, Harissi-Dagher M. The treatment of end-stage corneal disease: penetrating keratoplasty compared with Boston type 1 keratoprosthesis. *Graefes Arch Clin Exp Ophthalmol.* 2022 Sep;260(9):2781–2790. doi:10.1007/s00417-022-05646-1. Epub 2022 Apr 6. PMID:35384455
- Tan A, Tan DT, Tan XW, Mehta JS. Osteo-odonto keratoprosthesis: systematic review of surgical outcomes and complication rates. *Ocul Surf.* 2012 Jan;10(1):15–25. doi:10.1016/j.jtos.2012.01.003. Epub 2012 Jan 8. PMID:22330056
- Sayegh RR, Ang LP, Foster CS, et al. The Boston keratoprosthesis in Stevens-Johnson syndrome. *Am J Ophthalmol.* 2008;145:438–444.
- Solomon A, Ellies P, Anderson DF, Touhami A, Grueterich M, Espana EM, et al. Long-term outcome of keratolimbal allograft with or without penetrating keratoplasty for total limbal stem cell deficiency. *Ophthalmology.* 2002 Jun;109(6):1159–66. doi:10.1016/s0161-6420(02)00960-0. PMID:12045060
- Tóth G, Lukács A, Schirra F, Sándor GL, Killik P, Maneschg OA, et al. Ophthalmic Aspects of Stevens-Johnson Syndrome and Toxic Epidermal Necrolysis: A Narrative Review. *Ophthalmol Ther.* 2023 Aug;12(4):1795–1811. doi:10.1007/s40123-023-00725-w. Epub 2023 May 4. PMID:37140876; PMCID:PMC10157599