



Review of current knowledge about infections accompanied by paediatric acute lymphoblastic leukemia with emphasis on challenges regarding the treatment of refugees

Paulina Miciuda^{1,A-D}, Marika Jerzak^{1,A-D}, Natalia Olbrot^{1,A-D}, Katarzyna Karska^{2,E-F},
Monika Lejman^{3,E-F}, Joanna Zawitkowska^{4,A,E-F}

¹ Student Scientific Society of Department of Paediatric Haematology, Oncology and Transplantology, Medical University, Lublin, Poland

² Department of Pediatric Hematology, Oncology and Transplantology, University Children's Hospital, Lublin, Poland

³ Laboratory of Genetic Diagnostics, Medical University, Lublin, Poland

⁴ Department of Paediatric Haematology, Oncology and Transplantology, Medical University, Lublin, Poland

A – Research concept and design, B – Collection and/or assembly of data, C – Data analysis and interpretation, D – Writing the article, E – Critical revision of the article, F – Final approval of the article

Miciuda P, Jerzak M, Olbrot N, Karska K, Lejman M, Zawitkowska J. Review of current knowledge about infections accompanied by paediatric acute lymphoblastic leukemia with emphasis on challenges regarding the treatment of refugees. *Ann Agric Environ Med*. doi: 10.26444/aaem/195393

Abstract

Introduction and Objective. Children suffering from cancer or other blood disorders have a good chance of recovery. Interruptions in treatment, however, may have a negative impact on the final outcome. External factors, such as evacuation from conflict zones, contribute to vulnerability to infections and constitute a factor for the discontinuation of therapy. The aim of the review is to present recent knowledge of catheter-related sepsis and tuberculosis (TB) in children with acute leukemia. The case is also presented of an adolescent male of Ukrainian origin. The study draws attention to the challenges in treating patients from other regions due to differences in health status.

Review Methods. The article presents a rare case report connected with a literature review, based on the Google Scholar, PubMed and Web of Science databases from recent years.

Brief description of the state of knowledge. Many factors increase susceptibility to infections. Both leukemia itself as well as its intensive therapy influence immunosuppression. Invasive procedures disrupt physiological barriers. The presence of a central or peripheral catheter poses a main source of bloodstream infection. Deficiencies of immunity are conducive to reactivation of latent diseases such as TB, to which children are prone to develop severe forms. Therefore, treatment of latent TB infection (LTBI) in paediatric patients is crucial. In diagnosis, vigilance is particularly important in patients coming from high incidence regions with low vaccine coverage.

Summary. Discontinuation of therapy due to infection or other external circumstances may contribute to treatment failure. Early detection is significant to prevent complications of diseases and interruptions in chemotherapy. In medical care for immigrants, the epidemiological situation of the country of origin should be taken into account.

Key words

children, tuberculosis, acute lymphoblastic leukemia, latent tuberculosis, Ukraine, catheter-related sepsis

INTRODUCTION AND OBJECTIVE

The various difficulties associated with war directly and indirectly affect the sick. Children with cancer or other blood disorders are particularly susceptible. Although such patients have a high chance of survival, interruptions in treatment caused by external factors can lead to delay or even discontinuation of the therapy, consequently resulting in an increased mortality rate [1]. The health status of refugee children should be evaluated having regard to the country of origin. Differences between vaccination programmes, neonatal and screening tests, should be taken into consideration [2, 3].

In Ukraine, the current situation forced many citizens to interrupt treatment and evacuate to other European countries, including Poland [4]. Stress associated with war experiences and difficult social circumstances are also related to the well-being of children, and may contribute to a greater vulnerability to infections. An additional risk factor is the low vaccine coverage in Ukraine [5].

The aim of the study is to present recent knowledge on catheter-related sepsis, based on a literature review and diagnostic and therapeutic challenges of tuberculosis (TB) in children with acute leukemia. The clinical case is also presented of a 15-year-old boy of Ukrainian origin, undergoing treatment for acute lymphoblastic leukemia (ALL), diagnosed with catheter-related sepsis and latent tuberculosis infection (LTBI).

✉ Address for correspondence: Natalia Olbrot, Student Scientific Society of Department of Paediatric Haematology, Oncology and Transplantology, Medical University, Lublin, Poland
E-mail: nataliaolbrot@gmail.com

REVIEW METHODS

A literature review connected with a rare case report was carried out, aimed at summarizing current knowledge on catheter-related sepsis and tuberculosis in paediatric acute lymphoblastic leukemia (ALL). The majority of references used in the review were searched for on the PubMed platform. In order to find appropriate case reports, the Google Scholar and Web of Science platforms were also searched. The inclusion criteria for case reports were cases of children up to 18 years of age, diagnosed with tuberculosis during acute leukemia, focusing in particular on acute lymphoblastic leukemia. The exclusion criteria were case reports published before 2009. In the description of the study on leukemia complicated by sepsis, cases of children with immune disorders, genetic diseases and those in the Intensive Care Unit were also excluded. The research was performed using the following key words: 'acute lymphoblastic leukemia', 'catheter-related sepsis', 'tuberculosis', 'Ukraine', 'latent tuberculosis', and 'children'.

CASE REPORT

A fifteen-year-old male patient of Ukrainian nationality, with ALL, was admitted to the Department of Paediatric Haematology and Oncology at the Medical University in Lublin, eastern Poland. The patient was undergoing maintenance therapy according to the protocol ALL-intercontinental Berlin-Frankfurt-Munster protocol 2009 (ALL IC-BFM 2009), with 6-mercaptopurine and methotrexate. He presented with symptoms of fever, nausea and vomiting, pain in the left lumbar area that caused movement restriction, and stabbing chest pain. Symptoms persisted for up to 3 days. Physical examination revealed hepatosplenomegaly, abdominal ache, oedema of lower extremities, tachycardia, and herpes on the lips. The patient had a central venous catheter inserted into the right subclavian vein. Auscultation of the lungs revealed rhonchi and reduced vesicular murmur in the left base of haemithorax.

On admission, virological tests were performed: anti-HIV (Human Immunodeficiency Virus) and anti-HCV (Hepatitis C Virus) antibodies were non-reactive; anti-HBs (Hepatitis B Surface) antibodies were reactive. Laboratory diagnostics showed the following abnormalities (Tab. 1): elevated inflammatory parameters (Fig.1), anaemia, increased creatine kinase, marker of heart failure and clotting disorders. Blood and urine was collected for culture. The diagnosis of catheter-related sepsis was suspected. The central venous catheter was removed under general anesthesia. Antibiotic therapy with meropenem and vancomycin was started. Additionally, unfractionated heparin, antithrombin III and acyclovir were used.

The patient's condition deteriorated. In addition to the above symptoms, the boy developed dyspnoea that escalated while deep breathing, and cough with expectoration of purulent sputum with additive of blood. Previously collected microbiological culture confirmed sepsis. The presence of *Pseudomonas aeruginosa*, *Staphylococcus aureus* and *Candida* in blood was detected. *Pseudomonas aeruginosa* was sensitive to meropenem and *Staphylococcus aureus* sensitive to vancomycin; antibiotic therapy remained unchanged and voriconazole was added to the treatment

Table 1. Laboratory parameters

Factor	Day of hospitalization					standard
	1	2	5	6	8	
WBC [tys/ul]	4.55	3.84	4.08	3.75	4.58	3.50–10.50
RBC [mln/ul]	3.49	3.45	3.52	4.11	3.83	4.32–5.72
PLT [tys/ul]	36	68	129	181	292	140–420
ERS [mm/h]	44	-	-	-	-	2–15
Hb [g/dl]	11	10.8	11.1	12.9	12.1	13.5–17.5
Ht [%]	31.1	30.6	30.8	35.9	33.0	38.8–50.0
Neu [tys/ul]	3.18	2.69	2.14	1.28	2.23	2.50–7.00
aPTT [s]	48.7	-	37.2	36.3	-	25.4–36.9
ATIII [%]	76	-	105	110	-	83–128
D-D [ng/l]	2525	-	2180	2441	-	<500
Fg [g/l]	5.93	-	5.13	6.99	-	2.00–4.00
PT [s]	14.6	-	14.8	15.2	-	10.6–14.2
CK-MB [U/l]	56	-	14.7	-	-	0–25
CK [U/l]	1212	-	63.00	-	-	0–270
pro-BNP [pg/ml]	339.6	-	-	-	-	0–52

WBC – white blood cells; RBC – red blood cells; PLT – platelets; ERS – erythrocyte sedimentation rate; Hb – haemoglobin; Ht – haematocrit; Neu – neutrophil; aPTT – activated partial thromboplastin time; ATIII – antithrombin III; D-D – D-dimer; Fg – fibrinogen; PT – prothrombin time; CK-MB – creatine kinase myocardial band; CK – creatine kinase; pro-BNP – pro-B-type natriuretic peptide; CRP – C-reactive protein; PCT – procalcitonin

due to *Candida* detection. Computer tomography (CT) of the chest was performed, which showed focal infiltration of the lungs. The supreme alteration was in the left lung and resembled an abscess. Pleural effusion was present. The patient was examined by a surgeon, who saw no indication for drainage. Liposomal amphotericin B was introduced to the treatment as a consequence of suspicion of bacterial and fungal pulmonary co-infection. Due to the chest pain, angio-CT was performed. The radiological record excluded pulmonary embolism. A bone marrow aspiration biopsy was performed and ALL relapse was eliminated. Since the patient had not been immunized with Bacillus Calmette-Guerin (BCG) vaccination, TB was suspected. QuantiFERON-TB was performed and the outcome was positive.

The patient was transferred to the Centre for the Treatment of Lung Diseases and Tuberculosis for further diagnostics and treatment. On admission, his general condition was fair. He did not have fever and during auscultation no phenomenals were found. Laboratory tests showed no abnormalities in inflammatory parameters and morphology. Tests for TB were performed – interferon γ release assays (IGRA) and tuberculin skin test (TST), which came back positive. During bronchoscopy, material was collected for histopathological examination. There were no abnormalities consistent with TB, but changes consistent with chronic inflammation were noted. Genetic material of *Mycobacterium* was not detected neither in bronchial rising nor in sputum. The diagnosis was LTBI. Treatment using rifampicin started and was set to last for 3 months, co-administered with previously prescribed antibiotics and antifungal drugs. The tolerance to the therapy was good. Followed-up CT chest scans were performed after one month since treatment, and rifampicin started. Improvement was observed and previously noticed alterations regressed. Continuation of maintenance therapy of ALL was implemented to start 4 weeks after the therapy when rifampicin had ended.

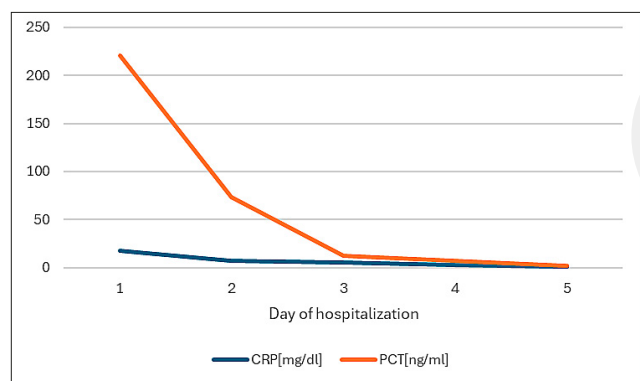


Figure 1. Inflammatory parameters

DESCRIPTION OF THE STATE OF KNOWLEDGE

Vulnerability to infections. Infections are the most common reason for treatment-related morbidity and mortality among children and adolescents with ALL, resulting in a mortality rate of 4%. They can lead to organ impairment and adjustments or delays in chemotherapy [6]. The most frequent is bacterial etiology, followed by fungal and viral. Mixed bacterial and fungal infections seem to pose the greatest risk [7]. Many factors influence susceptibility to infections in paediatric acute leukemia, resulting from suppression of the immune system caused by therapy leading to myelosuppression, as well as leukemia itself and the presence of non-functioning lymphocytes [8]. Chemotherapy can lead to pancytopenia which include leukocytopenia $<1.000/\mu\text{L}$, thrombocytopenia and profound anaemia. Neutropenia especially contributes to the vulnerability of the patients to the infections [9–11]. During treatment, which may consist of haematopoietic stem cells, bone marrow transplantation and frequent transfusions [9], the body's natural barriers are violated. Drug administration intravenously or even intrathecally, may constitute a portal of infection and pose a risk of bloodstream infection [8].

Sepsis is described as a medical condition characterized by a lack of specific treatment and a high mortality rate. Actions should be initiated immediately with empirical antibiotic therapy, including clinical condition of the patient, allergies and local resistance patterns. Subsequent therapeutic procedures should be based on blood culture results and modified in accordance with the obtained antibiograms susceptibility testing. If the catheter is removed, appropriate system therapy should last 10–14 days; however, patients with retained catheters should receive targeted antibiotic therapy for 10–14 days after negative blood culture, including every lumen of the catheter [12–14].

Central line-associated bloodstream infection. The source of 40–60% of all bloodstream infections are central and peripheral catheters [15]. The following factors particularly predispose to the development of central line-associated bloodstream infection (CLABSI): age below 1-year-old, prolonged catheter dwell time (more than 8 days), placement of central venous catheter (CVC) in subclavian or jugular vein, insertion site, cardiac disease as co-morbidity, malnutrition or obesity, and therapy with carbapenem or aminoglycoside [9]. CLABSI can be triggered by both Gram-positive and Gram-negative bacteria. In children with long dwell-time, Gram-negative bacteria occurred more frequently [16].

In an observational study by Kiyoshi Moriyama et al., the most common pathogens included *Pseudomonas aeruginosa* – 11%, *Klebsiella pneumoniae* – 10%, *Escherichia coli* – 8%, and *Staphylococcus aureus* – 6% [17]. Other customary causes can be induced by fungi, especially *Candida spp* [18]. Despite appropriate antibiotic therapy even 25% of CLABSI episodes end with failure, including reoccurrence of the infection [12]. Hsing-Chen Tsai et al. performed study of effectiveness of antibiotic lock therapy (ALT) among 146 patients (90 with primary diagnosed with ALL) with a total number of 246 CLABSI. During the study, predominant pathogens included *Enterobacteriaceae* (40.2%) and coagulase-negative *staphylococci* (CoNS; 20.7%). After obtaining blood cultures, principal anti-microbials and doses were administered. The severity of the clinical condition, identified pathogen and response to treatment, determined whether catheter removal was performed. However, fungal infection resulted in a higher risk of port removal (66.7%) and mortality rate (33.4%). The frequently used anti-microbials included vancomycin 5 mg/ml, amikacin 2mg/ml, ciprofloxacin 1 mg/ml, ampicillin 2 mg/ml, amphotericin B 2.5mg/ml, among others. The total success rate of ALT treatment was 58.6% for CoNs and 78.3% for *Enterobacteriaceae* infections. No significant side-effect was observed during study [19].

The crucial role of catheter removal was shown in research performed by Ewelina Gowin et al. In the study, 49% of children with bacteraemia needed to have early port removal – within 14 days of bloodstream infections. The removal of a catheter is crucial to sepsis caused by fungi (*Candida* species), or multi-drug resistant pathogens. However, bloodstream infections caused by coagulase-negative *Staphylococcus*, *Corynebacterium jeikeium*, or *Pseudomonas aeruginosa* can be successfully treated without removal of the CVC. Also, in the case of negative microbiological tests results of both port and peripheral vein co-existing with symptoms of infection like fever, catheter removal should be considered due to the possibility of occurrence of catheter-related infection not detected in blood cultures [20]. In addition, Ji et al. highlighted the necessity of immediate removal of port the after termination of thrombosis, occlusion, chemotherapy or CLABSI caused by *Bacillus*, *Staphylococcus*, *Pseudomonas*, *Corynebacterium jeikeium* and *Candida* species [21].

Challenges in healthcare of refugees. The presented case described the medical history of an adolescent patient of Ukrainian-origin with ALL, admitted to hospital with symptoms of infection. Catheter-related sepsis was suspected; therefore, the decision was made to remove the catheter placed in the right subclavian vein. Diagnosis was confirmed by microbiological culture. Due to deterioration in the patient and lack of BCG vaccination in the medical history, the QuantiFERON-TB test was conducted which resulted in a positive outcome. In the Centre for the Treatment of Lung Diseases and Tuberculosis, the patient underwent further diagnosis: IGRA and TST. The results were positive. Genetic material of *Mycobacterium tuberculosis* was not detected. Thus, the diagnosis of LTBI was made.

Ukraine is one of the European countries with the highest incidence of TB in which many cases still remain undetected. The WHO recommends a vaccination coverage of 95%, whereas in Ukraine there under-vaccination rate is 77% [22].

The military conflict in Ukraine forced many inhabitants to leave their homeland and seek shelter abroad [23]. In 2022,

the total number of Ukrainian citizens in Poland reached around 2 million, with women and children representing the majority of refugees. The children are particularly prone to the transmission and progression of infections, such as *Mycobacterium tuberculosis* among the active diseases. They belong to a group with a higher mortality rate, and therefore require increased medical attention [24].

The issue of tuberculosis in immunocompromised patients. One of the factors that promotes reactivation of latent infections are deficiencies of both humoral and cellular immunity [25]. Cases of TB are more frequent among patients with haematological malignancies. Nowadays, therapies used to treat haematological cancers have greater immunosuppressive effects than those applied previously [26]. According to statistics, it can be assumed these patients have a 2 – 40 times higher risk of developing TB than the general population. The overlapping of cancer and TB can lead to misdiagnose as the latter disease may manifest itself non-specifically, especially in immunocompromised, underweight children [27]. Symptoms more or less specific to TB including fever, night sweats, weight loss, cough, and enlarged mediastinal lymph nodes which may also occur in childhood cancers. Respiratory manifestations may mask mediastinal masses such as lymphoma [28]. Detected lesions are rarely suspected of being of tuberculous etiology; a fungal infection is usually assumed [25].

The number of cases describing children with tuberculosis during ALL is limited. The following articles from the past 15 years were included in the current review after searching databases (Tab. 2).

Among the cases may be mentioned those confirmed as vaccinated [30, 33], with no history of TB contact [30, 32–34], and those exposed to TB infection [31, 35]. Patients were diagnosed with TB at various stages of treatment with ALL, such as newly- diagnosed [36] induction phase [29], maintenance phase [30, 32, 33], and during remission [31, 34]. In some patients [29, 31, 34], fungal etiology infection was suspected and anti-mycotic therapy was performed. Female patient had a TST performed before beginning chemotherapy as a screening [37]

Lesaca-Medina et al. enrolled 29 children aged between 1 – 18 years with acute leukemia – ALL or AML, while in the maintenance phase or a minimum of 1 year from the last dose of chemotherapy. The aim was to assess the incidence of TB infection or disease among children with acute leukemia in the maintenance phase of treatment. All patients were vaccinated, 6 were exposed to contact with people diagnosed with TB. The children underwent a TST in which positive results were reported 13 times, which constituted 45% of patients [39]. Cruz et al. reported 6 children treated for TB: 5 with malignancies, 3 of them haematologic, and 1 had undergone a bone marrow transplant. All presented with fever. The culture was positive in 5 out of 6 cases, and 4 out of 5 TSTs performed were positive, one time it was not conducted. After the transplantation, the patient developed respiratory failure which resulted in death. Post-mortem blood and lung biopsy revealed the presence of *Mycobacterium tuberculosis* [40]. In the case series reported by Cruz et al. which included 45 children under 18 years of age with pleural TB, only one 5-year-old boy suffered from ALL and immunodeficiency [41].

Table 2. Reported cases of TB in children with ALL (2009 – 2024)

References	Age and x of patient	Symptoms	Type	Diagnostic method	Treatment
Panda et al, 2015 [29]	5-year-old female	Prolonged fever	EPTB	laparoscopy and biopsy	No data available
Zivanovic et al, 2010 [30]	14-year-old male	Fever, sweating, cough, general fatigue, decreased breath sound in left middle and lower lung area	PTB and EPTB	Chest X-ray, CT-scan, AFB staining (sputum), MTB culture	INH, RIF, PZA, EMB, prednisone
Lancioni et al, 2009 [31]	2.5-year-old male	High fever 39.4	PTB	CT-scan, biopsy, AFB staining, PCR for MTB, MTB culture	INH, RIF, PZA, azithromycin, EMB
Das et al, 2014 [32]	9-year-old female	Tender, soft-tissue swelling over back	EPTB	MRI, Imagine-guided aspiration, AFB staining, MTB culture, TST	INH, RIF, PZA, EMB
Trisiana et al, 2021 [33]	16-year-old male	Fever, cough, pain in the left side of the chest, weight loss	EPTB	Chest X-ray, pleural effusion puncture	INH, RIF, PZA, EMB, prednisone
Lee et al, 2011 [34]	17-year-old male	Fever	PTB	AFB staining (sputum), chest X-ray, MTB culture	INH, RIF, PZA, EMB; levofloxacin substituted for EMB, cycloserine for PZA
	14-year-old female	Fever, skin nodule	PTB and EPTB	CT-scan, BAL, AFB staining, MTB culture; biopsy, PCR for MTB	INH, RIF, PZA, levofloxacin; RIF substituted for cycloserine
Anwar et al, 2014 [35]	9-year-old male	Prolonged fever, face and upper chest swelling, difficulty in breathing, chylothorax	EPTB	Chest X-ray, pleural effusion aspiration	broad spectrum antibiotics, anti-tubercular drugs, steroid
Sahoo et al, 2014 [36]	18-year-old male	Lymphadenopathy and increasing dyspnea, chylothorax	EPTB	Chest X-ray. PCR for MTB	anti-tubercular drugs
Iamwat et al, 2023 [37]	9-year-old female	Prolonged fever, persistent cough	PTB	CT-scan, AFB staining (tissue sample), PCR for MTB	levofloxacin – the only mentioned
Pawińska-Wasikowska et al, 2020 [38]	15-year-old male	Nodules on the skin of the face and trunk; chest wall pain on the left side; HLH	EPTB	X-ray, puncture of pleura	INH, RIF

INH – isoniazid; RIF – rifampicin; PZA – pyrazinamide; EMB – ethambutol; AFB – acid fast bacilli; MTB – *Mycobacterium tuberculosis*; EPTB – extrapulmonary tuberculosis; PTB – pulmonary tuberculosis; BAL – bronchoalveolar; CT – computed tomography; PCR – polymerase chain reaction; TST – tuberculin skin test; HLH – haemophagocytic lymphohistiocytosis.

Children are prone to developing severe and disseminated forms of TB; therefore, treatment of LTBI in paediatric patients is especially important [42]. Early detection of TB infection through screening methods enable the implementation of appropriate treatment and the prevention of developing the active disease [43]. The Public Health Agency of Canada recommended screening for LTBI among all haematological cancers patients [44]. The currently available screening tests are TST and IGRAs. Nevertheless, test results may be false negative in immunocompromised individuals, with false positives in the case of TST in BCG-vaccinated patients [45]. The first line examinations are radiography and ultrasonography. The gold standard in diagnosis is *Mycobacterium tuberculosis* culture and PCR. However, in the paediatric group it may prove difficult to collect appropriate samples [46]. In children unable to expectorate, specimens can be taken of gastric lavage, aspirate or induced sputum. These methods have sensitivity of 60–70%, which increases with the number of samples taken [47].

SUMMARY

Infections in paediatric patients contribute to interruptions in therapy and pose a risk of treatment failure, thereby increasing the mortality rate. Apart from immunosuppression concurrent with chemotherapy, external factors such as evacuation from conflict zones, influence the final outcome. Additional challenges are diagnostic and the treatment of refugees due to the differences in the incidence of infectious diseases in specific regions. Variations in the local health care system, including obligatory vaccinations, should be taken into consideration in planning treatment process. In daily practice, doctors increasingly encounter incidences of diseases that are atypical for a given region. Early detection of infections is crucial to prevent progression to severe forms of diseases and further complications.

REFERENCES

- Agulnik A, Kizyma R, Salek M, et al. Global effort to evacuate Ukrainian children with cancer and blood disorders who have been affected by war. *Lancet Haematol*. 2022;9(9):645–647. [https://doi.org/10.1016/S2352-3026\(22\)00259-9](https://doi.org/10.1016/S2352-3026(22)00259-9)
- Shetty AK. Infectious Diseases among Refugee Children. *Children (Basel)*. 2019;6(12):129. <https://doi.org/10.3390/children6120129>
- Ludvigsson JF, Loboda A. Systematic review of health and disease in Ukrainian children highlights poor child health and challenges for those treating refugees. *Acta Paediatr*. 2022;111(7):1341–1353. <https://doi.org/10.1111/apa.16370>
- Stephenson J. Public Health Agency Outlines Guidance on Infectious Disease Risks for Ukrainian Refugees. *JAMA Health Forum*. 2022;3(3):220838. <https://doi.org/10.1001/jamahealthforum.2022.0838>
- Pluta M, Karny K, Lipińska M, et al. Ukrainian War Refugee Children With Particularly Severe Viral Infections: A Case Series Report. *Pediatr Infect Dis J*. 2024;43(2):30–36. <https://doi.org/10.1097/INF.0000000000004162>
- Wolf J, Tang L, Flynn PM, et al. Levofloxacin Prophylaxis During Induction Therapy for Pediatric Acute Lymphoblastic Leukemia. *Clin Infect Dis*. 2017;65(11):1790–1798. <https://doi.org/10.1093/cid/cix644>
- Quattrone M, Di Pilla A, Pagano L, et al. Infectious complications during monoclonal antibodies treatments and cell therapies in Acute Lymphoblastic Leukemia. *Clin Exp Med*. 2023;23(6):1823–1833. <https://doi.org/10.1007/s10238-023-01000-9>
- van de Velde ME, El Hassani SEM, Kaspers GJL, et al. Prediction of Bloodstream Infection in Pediatric Acute Leukemia by Microbiota and Volatile Organic Compounds Analysis. *J Pediatr Hematol Oncol*. 2022;44(1):152–159. <https://doi.org/10.1097/MPH.0000000000002210>
- Baier C, Linke L, Eder M, et al. Incidence, risk factors and healthcare costs of central line-associated nosocomial bloodstream infections in hematologic and oncologic patients. *PLoS One*. 2020;15(1):0227772. <https://doi.org/10.1371/journal.pone.0227772>
- Lafuente Cabrero E, Terradas Robledo R, Civit Cuñado A, et al. Risk factors of catheter-associated bloodstream infection: Systematic review and meta-analysis. *PLoS One*. 2023;18(3):0282290. <https://doi.org/10.1371/journal.pone.0282290>
- Tölle D, Hentrich M, Pelzer BW, et al. Impact of neutropenia on central venous catheter-related bloodstream infections in patients with hematological malignancies at the time of central venous catheter insertion: A matched-pair analysis. *Infect Control Hosp Epidemiol*. 2019;40(10):1204–1206. <https://doi.org/10.1017/ice.2019.224>
- Wolf J, Curtis N, Worth LJ, et al. Central line-associated bloodstream infection in children: an update on treatment. *Pediatr Infect Dis J*. 2013;32(8):905–910. <https://doi.org/10.1097/INF.0b013e3182996b6e>
- Hajjar N, Ting JY, Shah PS, et al. Blood culture collection practices in NICU: A national survey. *Paediatr Child Health*. 2023;28(3):166–171. <https://doi.org/10.1093/pch/pxac112>
- Thaden JT, Tamma PD, Doi Y, et al. Variability in oral antibiotic step-down therapy in the management of Gram-negative bloodstream infections. *Int J Antimicrob Agents*. 2021;58(6):106451. <https://doi.org/10.1016/j.ijantimicag.2021.106451>
- Timsit JF, Ruppé E, Barbier F, et al. Bloodstream infections in critically ill patients: an expert statement. *Intensive Care Med*. 2020;46(2):266–284. <https://doi.org/10.1007/s00134-020-05950-6>
- Berger I, Cohen T, Rahmani E, et al. Peripheral Venous Catheter-related Bloodstream Infections in Hospitalized Children: The Role of Gram-negative Bacteria. *Pediatr Infect Dis J*. 2021;40(11):395–399. <https://doi.org/10.1097/INF.0000000000003255>
- Moriyama K, Ando T, Kotani M, et al. Risk factors associated with increased incidences of catheter-related bloodstream infection. *Medicine (Baltimore)*. 2022;101(42):31160. <https://doi.org/10.1097/MD.00000000000031160>
- Supatharawanich S, Narkbunnam N, Vathana N, et al. Invasive Fungal Diseases in Children with Acute Leukemia and Severe Aplastic Anemia. *Mediterr J Hematol Infect Dis*. 2021;13(1):2021039. <https://doi.org/10.4084/MJHID.2021.039>
- Tsai HC, Huang LM, Chang LY, et al. Central venous catheter-associated bloodstream infections in pediatric hematology-oncology patients and effectiveness of antimicrobial lock therapy. *J Microbiol Immunol Infect*. 2015;48(6):639–646. <https://doi.org/10.1016/j.jmii.2014.07.008>
- Gowin E, Świątek-Kościelna B, Mańkowski P, et al. The Profile of Microorganisms Responsible for Port-Related Bacteremia in Pediatric Hemato-Oncological Patients. *Cancer Control*. 2020;27(1):1073274820904696. <https://doi.org/10.1177/1073274820904696>
- Ji L, Yang J, Miao J, et al. Infections Related to Totally Implantable Venous-Access Ports: Long-Term Experience in One Center. *Cell Biochem Biophys*. 2015;72(1):235–40. <https://doi.org/10.1007/s12013-014-0443-1>
- Wilczek NA, Brzyska A, Bogucka J, et al. The Impact of the War in Ukraine on the Epidemiological Situation of Tuberculosis in Europe. *J Clin Med*. 2023;12(20):6554. <https://doi.org/10.3390/jcm12206554>
- Instytut Gruźlicy i Chorób Płuc. Emergency People-Centered MDR-TB Response. Accessed May 12, 2024. Available online: <https://www.igichp.edu.pl/diagnostyka/zaklad-epidemiologii-i-organizacji-walki-z-gruzlicza/emergency-people-centered-mdr-tb-response/>
- Dahl V, Migliori GB, Lange C, et al. War in Ukraine: an immense threat to the fight against tuberculosis. *Eur Respir J*. 2022;59(4):2200493. <https://doi.org/10.1183/13993003.00493-2022>
- Jain A, Prakash G, Singh C, et al. Analysis of Clinical Profile and Outcome of Tuberculosis in Patients with Acute Leukemia. *Indian J Hematol Blood Transfus*. 2018;34(3):430–442. <https://doi.org/10.1007/s12288-017-0875-z>
- Cheng MP, Abou Chakra CN, Yansouni CP, et al. Risk of Active Tuberculosis in Patients with Cancer: A Systematic Review and Meta-Analysis. *Clin Infect Dis*. 2017;64(5):635–644. <https://doi.org/10.1093/cid/ciw838>
- Vadakkan Devassy T, K V S, Jacob A, et al. Tuberculosis and childhood cancer – A review of literature. *Indian J Tuberc*. 2023;70(1):39–48. <https://doi.org/10.1016/j.ijtb.2023.09.006>
- van Heerden JK, van Zyl A, Schaaf HS, et al. Childhood Cancers Misdiagnosed as Tuberculosis in a High Tuberculosis Burden Setting. *Pediatr Infect Dis J*. 2021;40(12):1076–1080. <https://doi.org/10.1097/INF.0000000000003330>

29. Radhakrishnan V, Sundersingh S, et al. Disseminated tuberculosis presenting as prolonged fever without source in a pediatric patient with acute lymphoblastic leukemia. *J Cancer Res Ther.* 2015;11(4):1043. <https://doi.org/10.4103/0973-1482.154030>
30. Zivanovic S, Saranac L, Kostic G, et al. A case of acute tuberculous pleuropneumonia in a patient with acute lymphoblastic leukemia. *Sci World J.* 2010;10:578–85. <https://doi.org/10.1100/tsw.2010.52>
31. Lancioni C, LaBeaud AD, Esper F, et al. Pulmonary tuberculosis presenting as fever without source in a pediatric patient with acute lymphoblastic leukemia. *Pediatr Blood Cancer.* 2009;53(7):1318–20. <https://doi.org/10.1002/pbc.22155>
32. Das A, Trehan A, Vyas S, et al. Multivertebral tubercular spondylodiscitis with abscesses in acute lymphoblastic leukemia. *Pediatr Hematol Oncol.* 2014;31(7):664–666. <https://doi.org/10.3109/08880018.2014.935838>
33. Trisiana DY, Yani FF. Tuberculous Pleural Effusion in Child with Acute Lymphoblastic Leukemia. *Science Midwifery.* 2021;9(2):338–344.
34. Lee JW, Kwon HJ, Jang PS, et al. Two children with differing outcomes after treatment for pulmonary tuberculosis diagnosed after allogeneic hematopoietic stem cell transplantation. *Transpl Infect Dis.* 2011;13(5):520–523. <https://doi.org/10.1111/j.1399-3062.2011.00641.x>
35. Anwar S, Rahman AKMM, Rahman ME, et al. Bilateral Chylothorax due to Disseminated Tuberculosis and Acute Lymphoblastic Leukemia in a young boy: A case report and Literature review. *Bangladesh J Child Health.* 2014;38(3):164–168.
36. Sahoo RK, Bakhshi S. Chylothorax at Presentation in T-Cell Acute Lymphoblastic Leukemia: The Milky Puzzle. *J. Pediatr Hematol Oncol.* 2014;36(8):663–4. <https://doi.org/10.1097/MPH.0b013e318290bcbc>
37. Iamwat W, Cheawcharnprapan K, Yenjabog P, et al. Aspergillosis and pulmonary tuberculosis co-infection in a 9-year-old with B-cell acute lymphoblastic leukemia. *Oxf Med Case Reports.* 2023;2023(8):omad082. <https://doi.org/10.1093/omcr/omad082>
38. Pawińska-Wa Sikowska K, Cwiklinska M, Wyrobek E, et al. Disseminated Juvenile Xanthogranuloma and Hemophagocytic Lymphohistiocytosis Developed During Treatment of Acute Lymphoblastic Leukemia: Case Report. *Front Oncol.* 2020;10:921. <https://doi.org/10.3389/fonc.2020.00921>
39. Lesaca-Medina, MY, Maramba-Lazarte C. “The Prevalence of TB infection and disease among children with acute leukemia.” *PIDSP Journal.* 2009;10(1):13–20.
40. Cruz AT, Airewele G, Starke JR. Tuberculosis in pediatric oncology and bone marrow transplantation patients. *Pediatr Blood Cancer.* 2014;61(8):1484–1485. <https://doi.org/10.1002/pbc.24985>
41. Cruz AT, Ong LT, Starke JR. Childhood pleural tuberculosis: a review of 45 cases. *Pediatr Infect Dis J.* 2009;28(11):981–984. <https://doi.org/10.1097/INF.0b013e3181a8568b>
42. Viswanathan VK. Latent TB infection in children and adolescents: Scientific rationale and programmatic management. *Indian J Tuberc.* 2023;70(1):35–38. <https://doi.org/10.1016/j.ijtb.2023.09.001>
43. Hasan T, Au E, Chen S, et al. Screening and prevention for latent tuberculosis in immunosuppressed patients at risk for tuberculosis: a systematic review of clinical practice guidelines. *BMJ Open.* 2018;8(9):022445. <https://doi.org/10.1136/bmjopen-2018-022445>
44. Taha R, Kothari S, Foroutan F, et al. Implementation of a Routine Screening Program for Latent Tuberculosis Infection among Patients with Acute Leukemia at a Canadian Cancer Center. *Curr Oncol.* 2022;29(12):9325–9334. <https://doi.org/10.3390/curroncol29120731>
45. Chin KL, Anibarro L, Sarmiento ME, et al. Challenges and the Way forward in Diagnosis and Treatment of Tuberculosis Infection. *Trop Med Infect Dis.* 2023;8(2):89. <https://doi.org/10.3390/tropicalmed8020089>
46. Pelosi U, Pintus R, Savasta S, et al. Pulmonary Tuberculosis in Children: A Forgotten Disease? *Microorganisms.* 2023;11(7):1722. <https://doi.org/10.3390/microorganisms11071722>
47. Rodrigues C, Singhal T. What is New in the Diagnosis of Childhood Tuberculosis? *Indian J Pediatr.* 2024;91(7):717–723. <https://doi.org/10.1007/s12098-023-04992-0>