



Into the dark of the black oesophagus

Anna Rycyk-Bojarzyńska^{1,A,D}✉, Beata Kasztelan-Szczerbińska^{1,C,E}, Halina Cichoż-Lach^{1,B,F}

¹ Department of Gastroenterology with Endoscopy Unit, Medical University, Lublin, Poland

A – Research concept and design, B – Collection and/or assembly of data, C – Data analysis and interpretation, D – Writing the article, E – Critical revision of the article, F – Final approval of the article

Rycyk-Bojarzyńska A, Kasztelan-Szczerbińska B, Cichoż-Lach H. Into the dark of black oesophagus. *Ann Agric Environ Med.* doi: 10.26444/aaem/176295

Abstract

Acute esophageal necrosis (AEN), known as black oesophagus or Gurvit's syndrome, is an extremely rare clinical syndrome. Patients usually present with life-threatening symptoms of upper gastrointestinal haemorrhage (70–90% of cases), as in this case report. Diagnosis of AEN is confirmed based on oesophagogastroduodenoscopy which reveals diffuse or patchy circumferential black necrotic oesophageal mucosa. The presented patient had some comorbidities, such as poorly controlled diabetes mellitus, secondary to chronic pancreatitis, hypertension, after cholecystectomy, addiction to alcohol and tobacco, and taking a small spoon of baking soda three times a day for a few months because of heartburn. Despite the poor prognosis of AEN, with mortality about 32–35%, most patients present with endoscopic improvement in short time – from 7 days to 1 month. Fortunately, the patient did not to have any complications in the course of AEN, and the treatment was effective.

Keywords

black oesophagus, Gurvit's syndrome, acute oesophageal necrosis (AEN), upper gastrointestinal hemorrhage, diabetes mellitus (DM)

List of abbreviations

AEN – acute oesophageal necrosis; **CMV** – cytomegalovirus; **CRP** – C-reactive protein; **DKA** – diabetic ketoacidosis; **DM** – diabetes mellitus; **EGD** – oesophagogastroduodenoscopy; **GFR** – glomerular filtration rate; **HSV** – herpes simplex virus; **PPI** – proton pump inhibitor; **TPN** – total parenteral nutrition

INTRODUCTION

Acute oesophageal necrosis (AEN) or esophageal stroke, also known as black oesophagus or Gurvit's syndrome, is an extremely rare clinical syndrome with a prevalence of 0.001–0.28% [1–3]. Patients usually present with life-threatening symptoms of upper gastrointestinal haemorrhage (70–90% of cases), evidenced as haematemesis, coffee-ground emesis, and melena [1, 4–9]. AEN's diagnosis is confirmed based on oesophagogastroduodenoscopy, which reveals diffuse or patchy circumferential black necrotic oesophageal mucosa [1, 2, 4]. The syndrome occurs predominantly in males compared to females (4:1) [2, 4, 10], who have multiple comorbidities with the peak incidence at the sixth decade of life [3, 4]. This can be explained by the fact that men are more likely to have atherosclerotic vascular disease than women [6, 11]. AEN has never been described without any comorbidities [7]. Risk factors for AEN are other comorbidities, such as diabetes mellitus (DM), diabetic ketoacidosis (DKA), hypertension, ischemia, shock, trauma, irradiation, lye ingestion, cardiovascular disease, peripheral artery disease, atherosclerosis, thromboembolic disease, gastric outlet obstruction, gastric volvulus, extreme dehydration, severe vomiting, microbial infection related to a nasogastric tube, chronic kidney disease, chronic liver disease, malnutrition, chronic alcohol abuse, infections (Herpes simplex), *Klebsiella pneumoniae*, *Lactobacillus acidophilus*, *Candida albicans*, cytomegalovirus, broad-spectrum antibiotics, hypothermia, Stevens–Johnson syndrome, anticardiolipin antibody syndrome, and malignancies (Tab. 1) [3, 5–7, 9, 12, 13].

✉ Address for correspondence: Anna Rycyk-Bojarzyńska, Department of Gastroenterology with Endoscopy Unit, Medical University, Lublin, Poland
E-mail: aniryck@op.pl

Received: 15.11.2023; accepted: 04.12.2023; first published: 27.12.2023

Table 1. Risk factors of black oesophagus

Risk factors of black oesophagus	
older age	extreme dehydration
diabetes mellitus	severe vomiting
diabetic ketoacidosis	malnutrition
hypertension	nasogastric tube
atherosclerosis	alcohol abuse
cardiovascular disease	broad-spectrum antibiotics
peripheral artery disease	infections
thromboembolic disease	Stevens–Johnson syndrome
ischemia	anticardiolipin antibody syndrome
shock	malignancy
trauma	lye ingestion
gastric outlet obstruction	chronic liver disease
gastric volvulus	chronic kidney disease
irradiation	hypothermia

The multifactorial etiology of the development of AEN remains unknown [5, 7, 12, 14, 15], although acid reflux and hypoperfusion are thought to be main underlying causes [12, 16]. Treatment of AEN is mostly supportive and consists on haemodynamic resuscitation, intravenous proton pump inhibitors (PPIs), oral sucralfate suspension, short-term parenteral renutrition, and nil-per-os restriction [4, 12, 17–19]. Early diagnosis is crucial to increase the chance of survival rates, and in the case of lack of comorbidities, the outcome is advantageous [2, 14, 18]. Mortality is 32–35% [2, 3]. Long-term complications of AEN are not common (about 10% of patients) but when they do appear they are severe, such as oesophageal stricture, perforation, stenosis or death [4, 9, 13, 15, 17]. Differential diagnosis includes melanosis,

malignant melanoma, pseudomelanosis, acanthosis nigrans, exogenous dye ingestion, coal dust exposure, adverse drug effects, pseudomembranous oesophagitis, and infections [7, 12, 13, 15, 17]. Patients with black oesophagus require long-term upper gastrointestinal endoscopy surveillance [8].

CASE REPORT

The case is presented of a 43-year-old male, with poorly controlled DM, admitted to the Department of Gastroenterology with the suspicion of acute upper gastrointestinal bleeding. The patient had black vomiting and melena for 2 days which was not confirmed in digital rectal examination. On admission, vitals were notable for saturation of 95% on oxygen therapy, hypotension with a blood pressure of 85/69 mm Hg, with tachycardia to 150/min. Physical examination of the abdomen showed tenderness in epigastric region. Laboratory work-up at admission revealed: blood pH – 6.96, haemoglobin – 11.3 g/dL, hematocrit – 35.5 %, white blood cells – $22.04 \times 10^3 / \mu\text{L}$ ($4.5\text{--}11.0 \times 10^3$) and platelet count – $319 \times 10^3 / \mu\text{L}$. Coagulation profile was normal: APTT – 25 sec. (25–36.9), PT – 12.2 sec. (9.4–12.5). Glucose level – 340 mg/dl (70–99), creatinine level – 4.14 mg/dl (0.7–1.3), urea level – 149 mg/dl (19–49), glomerular filtration rate (GFR) – 16.9ml/min/1.73m² (>90), potassium level – 6.18 mmol/l (3.5–5.1), and sodium level – 136 mmol/l (136–145). Lipase level was within normal ranges.

C-reactive protein (CRP) level – <0.5 mg/l. Chest radiography revealed possible air or small undescended points under left diaphragm. Medical history revealed that before admission the patient had been using a small spoon of baking soda 3 times a day for a few months because of heartburn. He also had diabetes mellitus secondary to chronic pancreatitis, hypertension, had a cholecystectomy a few years ago, and was addicted to alcohol and tobacco. He also admitted to non-steroidal anti-inflammatory drug use. The patient underwent urgent oesophagogastroduodenoscopy (EGD) which revealed multiple areas of black mucosa in all parts of the oesophagus, from the upper oesophageal sphincter to the gastroesophageal junction (Fig. 1–4).

Further examination was not attempted due to a high risk of perforation. These findings are typical for acute oesophageal necrosis. There was no evidence of *Helicobacter pylori*, cytomegalovirus (CMV), herpes simplex virus (HSV), *Candida albicans* infections or malignancy on further testing. The patient received high-dose oral proton pump inhibitors and sucralfate slurry. He was on a liquid diet and placed on total parenteral nutrition (TPN). Due to poorly controlled DM, he was consulted by the endocrinologist and was advised to receive infusion pump with insulin. After pharmacological treatment, all symptoms of the patient resolved and he was discharged. A follow-up gastroscopy is planned after 4 weeks.

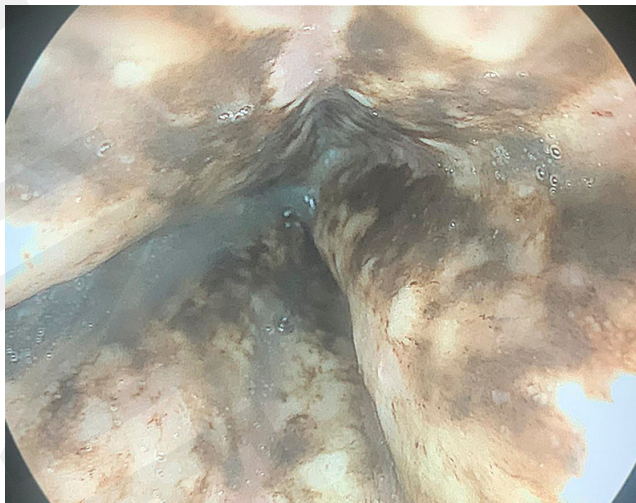

Figure 1. Middle oesophageal tissue necrosis

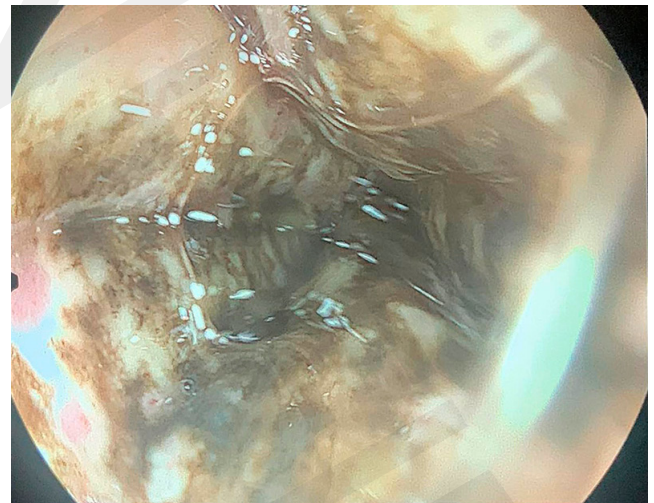

Figure 3. Middle oesophageal tissue necrosis

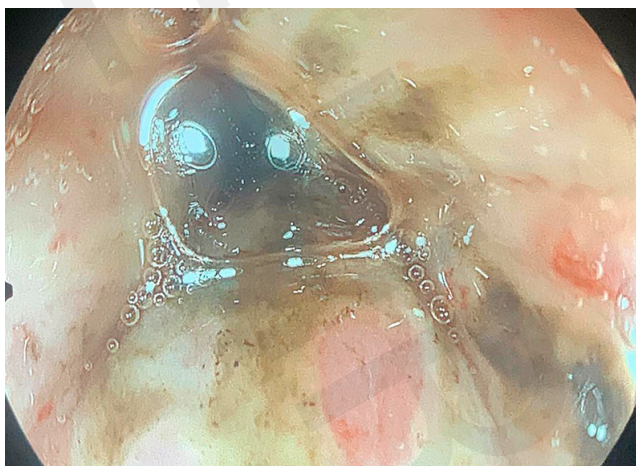


Figure 2. Middle oesophageal ulceration, erythema, and some necrosis

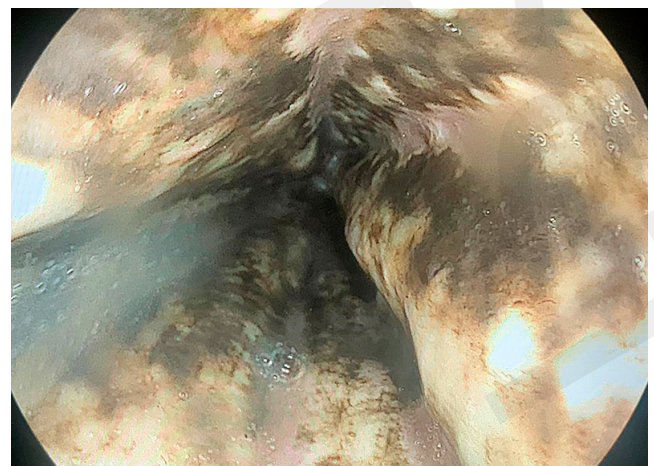


Figure 4. Middle oesophageal tissue necrosis

DISCUSSION

AEN was first reported in 1990 in a 82-year-old patient after cholecystectomy described by Goldenberg et al. [20]. In 2007, it was classified by Gurvits et al. as a distinct syndrome [3, 7]. Tanaka et al. reported the first case of recurrent AEN [21]. They presented the case of patient with AEN who had a recurrence of the disease on day 37 after finishing the PPI treatment [21]. Aggarwal et al. showed the first case of a patient with proximal AEN and COVID-19 infection [22]. Proximal location of black oesophagus has been described in only a few case reports [22, 23]. AEN appears primarily in the distal third of the oesophagus (in 97% of cases), compared to the proximal oesophagus [3, 7]. In a systemic review among 154 patients with AEN, upper endoscopy detected that 51% of patients had a distal disease, 36% had pan oesophageal, and 2% had a proximal disease [24]. In the same review, the mortality rate was 32%, while complications such as perforation and stricture formation occurred in 5% and 9%, respectively [24]. In the study by Chawla et al., despite AEN being detected in all parts of the oesophagus, the patient remained stable for the whole time of hospital treatment [25], which can lead to the hypothesis that the reach of necrosis does not affect survival. However, a study by the Mayo Clinic, revealed that the length of oesophageal involvement correlated with the days of hospitalization ($p=.05$) [26].

Although, AEN is said to be a rare disease, its prevalence is underestimated due to the lack of performing endoscopy examination among critically ill patients [27]. Despite the fact that upper gastrointestinal haemorrhage is the most common clinical presentation of black oesophagus, other symptoms may be presented, such as dysphagia, nausea, fever, epigastric pain, chest pain, and syncope [27–29]. It is therefore crucial to examine patients thoroughly due to the fact that chest pain can be the only manifestation of black oesophagus. In the USA, an 80-year-old patient with chest pain was admitted with non-ST-segment elevation myocardial infarction, but a cardiac catheterization did not reveal any critical stenosis [30]. The patient underwent an esophagogastroduodenoscopy which showed black oesophagus without active bleeding [30].

In the review by Rehman et al. the most common comorbidities seen in AEN patients were diabetes mellitus (24%), malignancy (20%), hypertension (20%), alcohol abuse (10%), and coronary artery disease (9%) [31]. The presented case involved at least 5 of the known risk factors: diabetes mellitus, acute kidney failure, alcohol abuse, smoking, and probably the intake of baking soda. However, in the medical literature, the case is reported of a 76-year-old patient who had no possible etiological factors of AEN, except for old age, generalized atherosclerosis, and a clinically silent hypotensive episode [32]. Nowadays, we know that hyperglycaemia is detected in 90% of patients with oesophageal necrosis, which causes diabetes mellitus to be one of the most common factors for AEN [33]. It has been confirmed by some data that AEN is strongly associated with diabetic ketoacidosis in acute gastrointestinal bleeding [34–43]. It is suggested by the researchers that hyperglycaemia in the course of DKA causes poor vascular flow which leads to damage of the oesophageal mucosal barrier [34]. Therefore, it provokes depletion volume depletion and hypoperfusion of the distal oesophagus, causing ischemia, and subsequently, necrosis of this oesophageal area [34]. Among the possible risk

factors of black oesophagus, a large paraoesophageal hiatal hernia has been described [44], which caused Cameron ulcers and gastric volvulus. Other cases of hiatal hernia causing AEN have also been revealed [45–48]. German researchers presented a case of CMV oesophagitis presenting as AEN after kidney transplantation [49]. In another kidney transplant recipient, on day 3 after operation, the patient was diagnosed with black oesophagus [50]. Both studies indicate that immunosuppression could be another risk factor for AEN development [49, 50], despite the fact that surgery is also a cause for physiologic stress [51].

As life expectancy is still increasing, older age and comorbidities remain the main factors for AEN development. An Italian study showed that the mean age of diagnosis to be 70 [52]. However, in the medical literature, a 13-year-old patient with diabetes type 2 and obesity was confirmed with the diagnosis of black oesophagus [53]. The etiopathogenesis of AEN arises from a ‘two-hit’ phenomenon which includes impaired mucosal barrier system and injury caused by reflux of acid and pepsin [54–57] (Fig. 5).

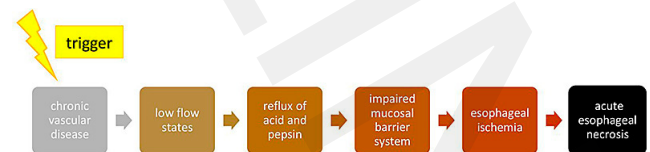


Figure 5. Etiopathogenesis of black oesophagus

Endoscopy necrosis of oesophageal mucosa is pathognomonic for black oesophagus [58]. Lipofuscin pigment, which is accumulated due to ischemia, causes the black colour of the oesophagus [16]. As mentioned before, it mostly appears in the distal oesophagus at the gastro-oesophageal junction, due to being a watershed and a less vascularized area of the oesophagus [16]. These areas are supplied by the most distal branches of the arteries and are susceptible to be ischemic [16]. The fact of poor oesophageal vascularization leads to rapid mucosa injury of the distal oesophagus, which is less vascularized compared to the middle and proximal segments [27, 59]. Furthermore, possible etiological factors of AEN, such as malignancy or gastric volvulus causing gastric obstruction, lead to the accumulation of gastric contents and their return to the oesophagus, which worsens the ischemic injury [27]. According to Hong et al., massive reflux disease can also lead to AEN [60]. Persistent exposure of the oesophagus to gastric fluids causes a decrease in blood flow in the oesophageal mucosa and submucosa [60].

The diagnosis of black oesophagus is based on upper endoscopy [16]. There is no requirement to perform biopsy and subsequently, to accomplish histological examination for AEN diagnosis. However, if it is possible to obtain biopsy specimens which could help in differential diagnosis to exclude other possible causes of black oesophagus [16, 34]. In the study by Gurvits et al., endoscopic staging of black oesophagus is proposed (Tab. 2) [61, 62].

Table 2. The endoscopic staging of black oesophagus

stage 0	stage 1	stage 2	stage 3
•pre-necrotic normal oesophagus	•black circumferential oesophagus	•‘chess-board’ oesophagus	•re-epithelized oesophagus

Histopathology reports confirm diffuse necrosis among AEN patients [61, 63] and usually reveal necrotic epithelium, polymorphonuclear infiltrates, inflammatory changes, and necrosed mucous membrane [29]. Although some studies have shown black oesophagus in patients with duodenal involvement [5, 64], unfortunately, the etiology of the duodenal involvement remains unknown [5]. A possible explanation for this is that both the oesophagus and the duodenum receive blood from the celiac axis [27].

Most important in the treatment of AEN is fluid resuscitation and patient stabilization [65], as well as management of the underlying condition [58]. In the treatment, naso-gastric tubes should not be used because of the high risk of oesophageal perforation [16, 19]. Surgical procedure is needed when perforation or abscess formation occurs [9, 29, 66]. Among possible complications can be distinguished perforation (about 7% of cases), stenosis of the oesophagus (>10% of patients), and death (up to 30%) [3, 9]. High mortality is caused by an underlying disease while AEN-related mortality is around 5–6% [67, 68].

CONCLUSIONS

Despite the poor prognosis of AEN, most patients present with endoscopic improvement within a short time, from 7 days to 1 month [27, 62]. Although there are no clinical guidelines in AEN management, it seems reasonable to perform a repeat endoscopy 1 month after initial presentation [9, 69]. Delayed complications could appear a few weeks later [70]. The patient in the presented Case Report is a prime example of how that specific agents, such as baking soda, should not be utilised for any purpose other than the use indicated because, used together with the presence of other underlying conditions could be life-threatening. Fortunately, in this case, the patient did not have any complications in the course of AEN, and the treatment was effective.

REFERENCES

- Lamers CR, Mares WGN, Bac DJ. Black oesophagus: a case series and literature review of acute esophageal necrosis. *Scan J Gastroenterol.* 2018;53(10–11):1421–1424. doi:10.1080/00365521.2018.1513064
- Vohra I, Attar B, Almoghrabi A. Black Oesophagus Due to Acute Necrosis. *Clinical Gastroenterology and Hepatology.* 2021;19(2):e16. doi:10.1016/j.cgh.2019.12.039
- Siddiqi A, Chaudhary FS, Naqvi HA, Saleh N, Farooqi R, Yousaf MN. Black oesophagus: a syndrome of acute esophageal necrosis associated with active alcohol drinking. *BMJ Open Gastroenterol.* 2020;7(1):e000466. doi:10.1136/bmjgast-2020-000466
- Division of Gastroenterology, Department of Medicine, New York University Faculty of Medicine, Langone Medical Center, New York, USA, Gurvits GE. Black Oesophagus: Diagnostic Associations and Management Strategies. *Turk J Gastroenterol.* 2022;33(5). doi:10.5152/tjg.2020.20151
- Ota I, Ono M, Fukuda R, et al. A case of black oesophagus with duodenal involvement. *Clin J Gastroenterol.* 2021;14(4):975–979. doi:10.1007/s12328-021-01410-w
- Grudell ABM, Mueller PS, Viggiano TR. Black oesophagus: report of six cases and review of the literature, 1963–2003. *Diseases of the Oesophagus.* 2006;19(2):105–110. doi:10.1111/j.1442-2050.2006.00549.x
- Choksi V, Dave K, Cantave R, et al. “Black Oesophagus” or Gurvits Syndrome: A Rare Complication of Diabetic Ketoacidosis. *Case Rep Gastrointest Med.* 2017;2017:4815752. doi:10.1155/2017/4815752
- Sunkesula V, Danilewitz M. The Black Oesophagus: A Rare Association. *Gastroenterology.* 2020;159(4):e8–e10. doi:10.1053/j.gastro.2020.03.078
- Gurvits GE. Black oesophagus: acute esophageal necrosis syndrome. *World J Gastroenterol.* 2010;16(26):3219–3225. doi:10.3748/wjg.v16.i26.3219
- Aranda Escaño E, Prieto Calvo M, Perfecto Valero A, Tellaech de la Iglesia M, Gastaca Mateo M, Valdivieso López A. Black oesophagus after combined liver-kidney transplantation. *Gastroenterol Hepatol.* 2020;43(1):25–27. doi:10.1016/j.gastre.2019.07.008
- Rossouw J. Hormones, genetic factors, and gender differences in cardiovascular disease. *Cardiovascular Res.* 2002;53(3):550–557. doi:10.1016/S0008-6363(01)00478-3
- Day A, Sayegh M. Acute oesophageal necrosis: A case report and review of the literature. *Inter J Surgery.* 2010;8(1):6–14. doi:10.1016/j.ijsu.2009.09.014
- Thomas M, Sostre Santiago V, Suhail FK, Polanco Serra G, Manocha D. The Black Oesophagus. *Cureus.* 2021;13(10):e18655. doi:10.7759/cureus.18655
- Augusto F, Fernandes V, Cremers MI, et al. Acute Necrotizing Esophagitis: a Large Retrospective Case Series. *Endoscopy.* 2004;36(5):411–415. doi:10.1055/s-2004-814318
- Uyar S, Duman A, Tan A, et al. Black oesophagus. *Turk J Gastroenterol.* 2019;30(11):986–987. doi:10.5152/tjg.2019.181019
- Saleem S, Weissman S, Ahmad S. The black oesophagus and duodenum: a rare case report. *Gastroenterol Hepatol Bed Bench.* 2020;13(3):264–267.
- Akkinepally S, Poreddy V, Moreno A. Black oesophagus. *CCJM.* 2009;76(7):400–400. doi:10.3949/ccjm.76a.08102
- Hermet A, Lidove O, Grimbert S, Zeller V, Ducroquet F, Ziza JM. Nécrose aiguë de l'œsophage. *La Revue de Médecine Interne.* 2014;35(6):393–395. doi:10.1016/j.revmed.2013.06.006
- Haddad I, Alomari M, El Kurdi B, Al Momani L, Sanaka MR. A Case of Black Oesophagus. *Cureus.* 2019;11(9):e5577. doi:10.7759/cureus.5577
- Goldenberg SP, Wain SL, Marignani P. Acute necrotizing esophagitis. *Gastroenterol.* 1990;98(2):493–496. doi:10.1016/0016-5085(90)90844-q
- Tanaka K, Toyoda H, Hamada Y, et al. A relapse case of acute necrotizing esophagitis. *Endoscopy.* 2007;39(S 1):E305–E305. doi:10.1055/s-2007-966789
- Aggarwal N, Neupane R, Bhatia U, Singla A, Rana K. Isolated Proximal Black Oesophagus in a COVID-19 Patient. *Cureus.* 2023;15(3):e36311. doi:10.7759/cureus.36311
- Neumann DA, Francis DL, Baron TH. Proximal black oesophagus: a case report and review of the literature. *Gastrointestinal Endoscopy.* 2009;70(1):180–181. doi:10.1016/j.gie.2008.09.055
- Abdullah HM, Ullah W, Abdallah M, Khan U, Hurairah A, Atiq M. Clinical presentations, management, and outcomes of acute esophageal necrosis: a systemic review. *Expert Review of Gastroenterology & Hepatology.* 2019;13(5):507–514. doi:10.1080/17474124.2019.1601555
- Chawla GS, Kukova L, Behin DS. Unusual case of acute esophageal necrosis. *BMJ Case Reports CP.* 2022;15(2):e248084. doi:10.1136/bcr-2021-248084
- Colón AR, Kamboj AK, Hagen CE, et al. Acute Esophageal Necrosis: A Retrospective Cohort Study Highlighting the Mayo Clinic Experience. *Mayo Clinic Proceedings.* 2022;97(10):1849–1860. doi:10.1016/j.mayocp.2022.03.018
- Martins D, Marques R, Costa P, de Sousa JP. The dark side of the oesophagus. *Autops Case Rep.* 2021;11:e2021284. doi:10.4322/acr.2021.284
- Bonaldi M, Sala C, Mariani P, Fratus G, Novellino L. Black oesophagus: acute esophageal necrosis, clinical case and review of literature. *J Surg Case Rep.* 2017;2017(3):rjx037. doi:10.1093/jscr/rjx037
- Dziadkowiec KN, Reddy R, Marcus AJ. Acute Esophageal Necrosis Following Acetaminophen Overdose: An Unreported Cause of Black Oesophagus. *HCA Healthc J Med.* 2022;3(2):47–49. doi:10.36518/2689-0216.1082
- Yuridullah R, Patel V, Melki G, Bollu J. Acute esophageal necrosis masquerading acute coronary syndrome. *Autops Case Rep.* 2020;10(1):e2019136. doi:10.4322/acr.2019.136
- Rehman O, Jaferi U, Padda I, Khehra N, Atwal H, Parmar M. Epidemiology, Pathogenesis, and Clinical Manifestations of Acute Esophageal Necrosis in Adults. *Cureus.* 2021;13(7):e16618. doi:10.7759/cureus.16618
- Katsinelos P, Christodoulou K, Pilpilidis I, et al. Black Oesophagus: An Unusual Finding During Routine Endoscopy. *Endoscopy.* 2001;33(10):904–904. doi:10.1055/s-2001-17333
- Ali M, Khan N, Yaseen A, Raees A. Gurvits Syndrome: Black Oesophagus in the Postoperative Setting. *Cureus.* 2022;14(1):e21240. doi:10.7759/cureus.21240

34. Jaber F, Alsakrneh S, Sripada S, et al. "Black Oesophagus" or Gurgvits Syndrome: A Rare Cause of Upper Gastrointestinal Bleeding in Diabetic Ketoacidosis. *Cureus*. 2023;15(2):e34989. doi:10.7759/cureus.34989
35. Haghbayan H, Sarker AK, Coomes EA. Black oesophagus: acute esophageal necrosis complicating diabetic ketoacidosis. *CMAJ*. 2018;190(35):E1049. doi:10.1503/cmaj.180378
36. Ghoneim S, Shah A, Dalal S, Landsman M, Kyprianou A. Black Oesophagus in the Setting of Diabetic Ketoacidosis: A Rare Finding from Our Institution. *Case Rep Gastroenterol*. 2019;13(3):475–480. doi:10.1159/000504434
37. Rigolon R, Fossà I, Rodella L, Targher G. Black oesophagus syndrome associated with diabetic ketoacidosis. *World J Clin Cases*. 2016;4(2):56–59. doi:10.12998/wjcc.v4.i2.56
38. Shah AR, Landsman M, Waghray N. A Dire Presentation of Diabetic Ketoacidosis with "Black Oesophagus". *Cureus*. 2019;11(5):e4761. doi:10.7759/cureus.4761
39. Jeyalingam T, Shimamura Y, Teshima C. Endoscopic Resolution of Black Oesophagus With Treatment of Diabetic Ketoacidosis. *Clin Gastroenterol Hepatol*. 2018;16(6):e68–e69. doi:10.1016/j.cgh.2017.08.046
40. Field Z, Kropf J, Lytle M, Castaneira G, Madruga M, Carlan SJ. Black Oesophagus: A Rare Case of Acute Esophageal Necrosis Induced by Diabetic Ketoacidosis in a Young Adult Female. *Case Rep Gastrointest Med*. 2018;2018:7363406. doi:10.1155/2018/7363406
41. Kim YH, Choi SY. Black oesophagus with concomitant candidiasis developed after diabetic ketoacidosis. *World J Gastroenterol*. 2007;13(42):5662–5663. doi:10.3748/wjg.v13.i42.5662
42. Uhlenhopp DJ, Pagnotta G, Sunkara T. Acute esophageal necrosis: A rare case of upper gastrointestinal bleeding from diabetic ketoacidosis. *Clin Pract*. 2020;10(2):1254. doi:10.4081/cp.2020.1254
43. Choksi V, Dave K, Cantave R, et al. "Black Oesophagus" or Gurgvits Syndrome: A Rare Complication of Diabetic Ketoacidosis. *Case Rep Gastrointest Med*. 2017;2017:4815752. doi:10.1155/2017/4815752
44. Deliwala SS, Hussain MS, Ponnappalli A, Bachuwa G, Gurgvits GE. Black oesophagus, upside-down stomach and cameron lesions: cascade effects of a large hiatal hernia. *BMJ Case Reports CP*. 2021;14(11):e246496. doi:10.1136/bcr-2021-246496
45. Li CJ, Claxton BB, Block P, Reilly S, Manski S, Choudhary C. Acute Esophageal Necrosis Secondary to a Paraesophageal Hernia. *Case Rep Gastroenterol*. 2021;15(2):594–597. doi:10.1159/000517235
46. Hwang J, Weigel TL. Acute esophageal necrosis: "black oesophagus." *JLS*. 2007;11(1):165–167.
47. Matsumoto N, Oki E, Morita M, et al. Successful treatment of acute esophageal necrosis caused by intrathoracic gastric volvulus: report of a case. *Surg Today*. 2009;39(12):1068–1072. doi:10.1007/s00595-008-3983-4
48. Vrba R, Klos D, Kurfurstová D, Špička P. Gastric resection with intrathoracic anastomosis in a hiatal hernia – A case report. *Int J Surg Case Rep*. 2023;102:107809. doi:10.1016/j.ijscr.2022.107809
49. Trappe R, Pohl H, Forberger A, Schindler R, Reinke P. Acute esophageal necrosis (black oesophagus) in the renal transplant recipient: manifestation of primary cytomegalovirus infection. *Transplant Infect Dis*. 2007;9(1):42–45. doi:10.1111/j.1399-3062.2006.00158.x
50. Kroner PT, Chirila R, Purcarea MR, Tribus L, Wadei HM. Acute esophageal necrosis following kidney transplantation. *J Med Life*. 2021;14(2):284–286. doi:10.25122/jml-2021-0024
51. Sheikh AB, Mirza S, Abbas R, et al. Acute Esophageal Necrosis: An In-depth Review of Pathogenesis, Diagnosis and Management. *J Community Hosp Intern Med Perspect*. 2022;12(1):96–103. doi:10.55729/2000-9666.1020
52. Selvaggi F, Cichella A, Aceto GM, Innocenti P, Cotellese R. Acute esophageal necrosis syndrome. The 2021 update from an Italian survey and personal experience. *Ann Ital Chir*. 2022;93:656–662.
53. Quitadamo P, Caruso F, Buccì C, et al. Black oesophagus in an adolescent with type 2 diabetes. *Lancet Diab Endocrinol*. 2021;9(9):638. doi:10.1016/S2213-8587(21)00187-X
54. Khan H, Ahmed M, Daoud M, Philipose J, Ahmed S, Deeb L. Acute Esophageal Necrosis: A View in the Dark. *Case Rep Gastroenterol*. 2019;13(1):25–31. doi:10.1159/000496385
55. Sonavane A, Gupta D, Ambekar A, Nagral A. Acute esophageal necrosis: An uncommon entity. *J Postgrad Med*. 2021;67(2):115–116. doi:10.4103/jpgm.JPGM_635_20
56. Dias E, Santos-Antunes J, Macedo G. Diagnosis and management of acute esophageal necrosis. *Ann Gastroenterol*. 2019;32(6):529–540. doi:10.20524/aog.2019.0418
57. Stanko K, Dilmaghani S, Storm A. Acute Esophageal Necrosis Presenting as Acute Blood Loss Anemia. *Mayo Clinic Proceedings*. 2023;98(1):21–22. doi:10.1016/j.mayocp.2022.09.004
58. Ullah W, Mehmood A, Micaliy I, Khan MS. Comprehensive review of acute oesophageal necrosis. *BMJ Case Rep*. 2019;12(2):e227967. doi:10.1136/bcr-2018-227967
59. Inayat F, Hurairah A, Virk HUH. Acute Esophageal Necrosis: An Update. *N Am J Med Sci*. 2016;8(7):320–322. doi:10.4103/1947-714.187159
60. Hong JW, Kim SU, Park HN, Seo JH, Lee YC, Kim H. Black Oesophagus Associated with Alcohol Abuse. *Gut Liver*. 2008;2(2):133–135. doi:10.5009/gnl.2008.2.2.133
61. Gurgvits GE, Shapsis A, Lau N, Gualtieri N, Robilotti JG. Acute esophageal necrosis: a rare syndrome. *J Gastroenterol*. 2007;42(1):29–38. doi:10.1007/s00535-006-1974-z
62. Grigore M, Enache I, Chirvase M, et al. Acute Esophageal Necrosis in Acute Pancreatitis—Report of a Case and Endoscopic and Clinical Perspective. *Diagnostics (Basel)*. 2023;13(3):562. doi:10.3390/diagnostics13030562
63. Sako A, Kitayama J, Inoue T, Kaizaki S, Nagawa H, Suzuki H. Black oesophagus—cause? *Gut*. 2005;54(2):192. doi:10.1136/gut.2004.044784
64. Wanta K, Abegunde AT. Tacrolimus-Induced Acute Esophageal Necrosis. *ACG Case Rep J*. 2020;7(6):e00396. doi:10.14309/crj.0000000000000396
65. Brar TS, Helton R, Zaidi Z. Total Parenteral Nutrition Successfully Treating Black Oesophagus Secondary to Hypovolemic Shock. *Case Rep Gastrointest Med*. 2017;2017:4396870. doi:10.1155/2017/4396870
66. Sachar M, Argueta E, Gurgvits GE. Comprehensive Review: Acute Esophageal Necrosis in the Setting of Gastric Volvulus. *Dig Dis Sci*. 2023;68(5):1672–1676. doi:10.1007/s10620-023-07869-6
67. Averbukh LD, Mavilia MG, Gurgvits GE. Acute Esophageal Necrosis: A Case Series. *Cureus*. 2018;10(3):e2391. doi:10.7759/cureus.2391
68. Richards J, Wei R, Anjum F. Esophageal Necrosis. In: *StatPearls*. StatPearls Publishing; 2023. Accessed November 9, 2023. <http://www.ncbi.nlm.nih.gov/books/NBK572075/>
69. Kuiper GM, de Maat MFG, Read MD, et al. Surgical management of a perforated 'black oesophagus.' *ANZ J Surg*. 2021;91(7–8):E539–E541. doi:10.1111/ans.16565
70. Jaiswal P, Araujo JL. Acute Esophageal Necrosis Associated With Acute Pancreatitis. *ACG Case Rep J*. 2019;6(12):e00295. doi:10.14309/crj.0000000000000295