



Rehabilitation after replantation of a non-work-related finger amputation without vascular anastomosis – case report

Justyna Frasuńska^{1,A-F}  , Dominika Kostka^{2,B-D,F} , Beata Tarnacka^{1,3,C-F} 

¹ Department of Rehabilitation, Medical University of Warsaw, Warsaw, Poland

² Department of Internal Medicine, Endocrinology and Diabetes, Medical University of Warsaw, Warsaw, Poland

³ Department of Rehabilitation, National Institute of Geriatrics, Rheumatology and Rehabilitation, Warsaw, Poland

A – Research concept and design, B – Collection and/or assembly of data, C – Data analysis and interpretation, D – Writing the article, E – Critical revision of the article, F – Final approval of the article

Frasuńska J, Kostka D, Tarnacka B. Rehabilitation after replantation of non-work-related finger amputation without vascular anastomosis: a case report. *Ann Agric Environ Med*. doi: 10.26444/aaem/176089

Abstract

Work in agriculture carries the risk of trauma as a result of mechanization (farm equipment and machinery), location of cultivated areas, and multi-functionality. In agriculture, the hands were the most affected parts of the body which sustained injury. Successful suturing of a finger initially disqualified from replantation is rare. The case is presented of a 55-year-old patient who had a non-work-related finger amputation. In a surgical centre not belonging to the reference ones in plastic surgery in Poland, a doctor with six months of surgical experience performed the replantation without vascular reconstruction (the amputated distal part of the finger served as a biological dressing). Despite the lack of vascular reconstruction and unfavourable prognosis, the amputated fragment of the finger maintained a partial blood supply. Subsequent flap surgery in the plastic surgery department, and rehabilitation of the patient due to finger contracture, led to functional recovery of the finger.

Key words

finger amputation, replantation, rehabilitation

INTRODUCTION

Agriculture carries risks of trauma as a result of mechanization (farm equipment and machinery), location of cultivated areas, and multi-functionality. In addition to injuries related to the use of agricultural equipment, agricultural injuries can also result from farm housing and the production of renewable energy [1]. The hands were the most affected body part in agriculture which sustained an injury [1].

According to US data, traumatic finger amputations were estimated yearly with an incidence of 7.5/100,000 person-years [2]. The most common age groups are children under five years of age and people over the age of 65. The most common mechanism of digit injury among children is caused by a finger getting caught in a door, and among adults – accidents involving power saws [2, 3]. Major amputations are more common in males in all age groups [1–3], although according to the literature, the majority of traumatic finger/limb amputations in adults are not work-related [4].

Replantation of amputated limbs in agriculture is rarely performed and failures of such treatment have been reported in the literature [3]. Replantation aims to regain the function of the amputated limb and to restore normal anatomical and functional conditions, which affect the further treatment and rehabilitation of the patient. The success of replantation depends on the mechanism of injury, amputation height, and ischemia time of the amputated finger fragment, general vascular condition, microsurgical skills, and post-operative management [5–9].

This case report presents a situation in which, despite an unfavorable prognosis and reconstruction performed without vascular reconstruction by a surgeon inexperienced in plastic surgery, the attached finger fragment maintained a partial blood supply. Subsequent flap surgery in the plastic surgery department and rehabilitation of the patient due to finger contracture led to functional recovery of the finger.

CASE REPORT

A 55-year-old man sustained a non-work-related third finger amputation of the right hand while closing a garage door (finger cut off by a cord attached to the door, following the force caused by the falling door). The finger wound had torn tissue at the edges (crushing injury). X-ray of the hand 2 hours after the event (Fig. 1a) showed a fracture and bone loss of the distal part of the distal phalanx.

The patient was treated surgically in a hospital that does not have a plastic surgery department and does not specialize in the surgical treatment of similar injuries. In the ED, due to poor chances of survival of the replanted finger, it was suggested initially to the patient to reject the finger sewing procedure due to poor chances of survival of the replanted finger. Subsequently, 1% lignocaine anesthesia was applied to the wound which was cleaned, and the finger sutured without revascularization. Next, the wound was cleaned under the 1% lignocaine anesthesia, and the finger was sutured without revascularization (the amputated distal part of the finger was treated as a form of biological dressing) (Fig. 1b). The surgeon who performed the procedure had six months experience in the specialty, and no experience in plastic surgery.

 Address for correspondence: Justyna Frasuńska, Medical University, Warsaw, Poland
E-mail: frasunska@gmail.com

Received: 11.10.2023; accepted: 29.11.2023; first published: 20.12.2023

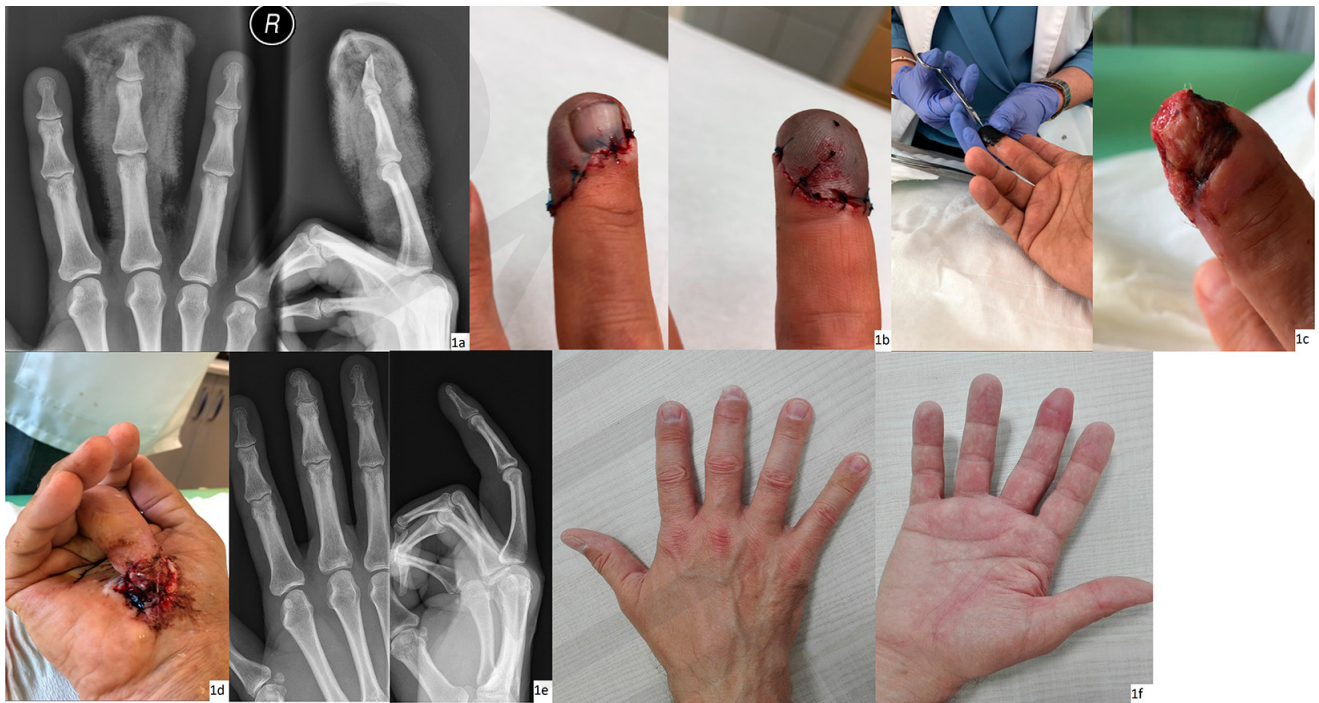


Figure 1a. Third finger X-ray performed on the day of injury; **Figure 1b.** 'Biological dressing' of the third finger of the right; hand (front and back view); **Figure 1c.** Escharectomy – removal of necrotic tissues, and deeper blood supply; **Figure 1d.** Lobe plastic surgery; **Figure 1e.** Third finger X-ray performed 2 months after injury; **Figure 1f.** Functional effect of the sewn amputated finger after surgery and rehabilitation

The patient was given tetanus anatoxin, prescribed amoxicillin+clavulanic acid, metronidazole, probiotic, diclofenac temporarily, pantoprazole, change of dressings every 2–3 days, and referred to a centre specializing in plastic surgery of the hand. Due to changes in the discolouration (blackening) of the skin of the transplanted finger, plastic surgeons negated the chances of saving the attached phalanx.

On day 23 after suture placement, necrosis of the fingertip was diagnosed (reference department). During the escharectomy, bleeding was observed from the deeper tissues in the base and edges of the wound (Fig. 1c). On the third day after the escharectomy, flap-plasty was performed (Fig. 1d). The operated hand was immobilized in a Zimmer splint for three weeks. Afterward, the skin-fat flap which was placed into the tissue defect of the sutured finger, needed a local plastic repairment of the skin and subcutaneous tissue. The hand was immobilized in a plaster cast. Two months after the surgery, an X-ray showed bone adhesion of the replanted phalanx (Fig. 1e).

Three months after the injury, the patient underwent a 6-week rehabilitation treatment programme. The aim of rehabilitation was to reduce swelling, contracture, and scar tissue, and to improve the grasping function of the hand (two-point, three-point, lateral, hook, cylinder, and concentric grasp). The program included: passive exercises, assisted exercises, manual therapy techniques, techniques to increase the range of motion in the inter-phalangeal joints (stretching exercises and decreasing joint contracture), exercises to increase muscle strength (resistance and instrumented exercises), manual hand function exercises (writing, holding small objects), elements of massage and physical therapy (magnetic field, laser therapy, hydrotherapy, thermotherapy, fango) to control scar, and swelling and sensory impact. The joint range of motion (based on the International SFTR

system) of finger II of the right hand improved (DIP-initial S:(-10)-0-(25), DIP-final S:(-5)-0-(75); PIP-initial S:(-35)-0-(70), PIP-final S:(-5)-0-(100); MCP-initial S:(-10)-0-(75), MCP-final S:(0)-0-(85)). Muscle strength of the right hand (based on the MRC scale) also improved, reaching maximum parameters after rehabilitation. Visually, a slight pinking of the distal phalanx, change in shape, and loss of subcutaneous tissue (no rounding of the finger) were observed (Fig. 1f), and palpation-smoothing of the scar. In the follow-up, there was a slight weakening of the three-point and two-point grips, compared to the contralateral side.

One year after the completion of rehabilitation, the patient reported sensory disturbances, hypersensitivity on the lateral phalanx, and increased cold intolerance of the replanted finger. He scored 2.5 points on the DASH scale in the limitations and symptoms sections and 0 points each on the 'work' and 'sport/play' modules. Activities that caused the patient little difficulties were: opening jars, turning the key in the lock, and changing the bulb in an overhead lamp. He reported not using this finger when typing on the keyboard, compared to the state before the injury. At the one-year follow-up after the completion of rehabilitation, the patient was satisfied with the final cosmetic (9/10) and functional (9/10) results, and denied complaints of finger pain (NRS=0).

DISCUSSION

In this case, the patient's sutured finger survived, despite the adverse survival conditions and in the absence of professional microsurgery.

The continuous development of implant techniques and interdisciplinary management allows achievement of better treatment results [5–7]. In the last 20 years, there has been

an increase in the rate of hospital admissions for finger amputation [2], and the predictive factors were white race, male gender, paediatric patients, and high-energy mechanism of injury [2].

According to the literature, the successful finger replantation rate is estimated to be between 57% – 95% [4–9]. The success of replantation is influenced by: the time since injury, mechanism of injury, time of ischemia of the amputated finger fragment, general vascular status (medical history of smoking, chronic diseases), microsurgical skills, and post-operative management (hygiene, care, monitoring, rehabilitation) [6–10]. The final decision for finger surgery should be taken based on the likelihood of survival, safety of the patient, ratio of treatment outcomes to resources, and the patient's motivation and expectations [5, 7].

Guillotine (sharp-cut) injury has the highest chance of replantation survival [6]. Crushed injury, characterized by localized crush area at the amputation site, is more common [5, 6].

A meta-analysis by Yu et al. showed no significant relationship between finger amputation height and replant survival [6]. In a distal amputation, the diameters of the blood vessels are small, making microsurgical repair technically challenging [10]. However, distal amputation, being less significant in hand function and outcome, results in less complicated and shorter rehabilitation, which may be a factor in the decision to perform replantation [7]. Indications for replantation include thumb amputations (important hand function) and multiple amputations (three or more fingers) [6, 10]. Patients with a replanted thumb have had better outcomes than patients with replantation of other fingers [12]. Amputation of a single finger other than the thumb, as in the presented case, has little effect on hand function impairment, and presumed longer treatment time, rehabilitation, and delayed return to work may make it less likely to be a determinant of the decision to replant.

The duration of ischemia of the amputated finger (>12h or <12h) is less important than the method of storage [6]. Better survival is observed when the finger was stored in ice bags, rather than stored at atmospheric temperature [6]. In the presented case, the ischemia time was two hours, the patient did not provide proper storage conditions when transporting the amputated finger, and the average temperature in Warsaw on the day of injury was about 16°C. In distal amputations, as in this case, the amputated phalanx fragment does not contain damaged muscle fragments (amputation of the finger distal to the attachment of the flexor digitorum superficialis muscle), which may affect better ischemia tolerance and give better functional results (better grip strength) [12].

In addition, personal factors (patient factors): age, gender, chronic diseases, and nicotine use, have an impact on the success of replantation [3, 7]. Old patients and children are less likely to have a successful replantation (vessel size and condition) [6]. Patients who smoke or have chronic diseases, for example, diabetes mellitus or hypertension, may have pathologically altered vessel walls which makes reconstruction and healing difficult [4]. In the presented case, the patient was not diagnosed with chronic diseases and did not smoke before the injury. Perhaps these factors could have favoured the positive outcome.

Replantation of distal phalanx fragments may give satisfactory final results, but it is associated with some technical or financial difficulties. Reposition-flap may give

worse final results (finger shortening, tendency to interphalangeal joint contracture, nail dystrophy) [4]. These techniques require specialized equipment, surgical skills, and surgery experience, and are associated with higher financial costs. In the microsurgery of amputated limbs, restoration of the vascular bed increases the chance of replant survival [10]. The problem of revascularization of distal phalanges is the small diameter of the vessels and/or the damage sustained, which make it difficult or impossible to restore vascular bed continuity without specialized equipment. However, this case and a similar one reported in the literature [11], show that the lack of vascular bed reconstruction provides the chance for the survival of deeper tissues. In addition, in the case described, no bone fixation (K-wires, plate, screw) or arthrodesis joint, were used, which could provide more stability to the added phalanx, and the sutured fragment of the finger was treated as a 'biological dressing'.

The success of replantation is influenced by the surgical experience, the presence specialized surgical equipment, and the development of large hand and plastic surgery centres [7]. In the presented case there was no surgical experience, professional equipment, nor access to a reference microsurgical centre.

Traumatic amputation is a stressful situation for the patient, affects the patient's quality of life [12], and may have psychological consequences. The patient's decision to 'replantation or termination' may be culturally, religiously, or professionally driven, and aesthetic considerations may outweigh the functional [7, 12]. In the presented case, the patient insisted on finger sewing. Perhaps the desire for a finger and a positive attitude toward treatment may have been a factor in healing. No studies have reported how a patient's emotions affect the outcome of amputation treatment.

Postoperative care should include adequate hydration, maintenance of hemodynamic stability, constant patient environment (warm rooms) to maintain a dilated vascular bed, maximize blood flow to the replanted part and reduce the risk of thrombosis in the anastomosed vessels [7–9]. According to the literature, the patients achieved better functional outcomes when actively engaged in the rehabilitation program and following the recommendations (continued rehabilitation at home, regular use of prescribed scales) [9]. Comprehensive therapeutic management can also improve the distant results of replantation [13]. Our patient did not take any medications, followed hygiene principles, kept his finger warm, and actively participated in the rehabilitation program, which may have influenced the positive outcome of the treatment.

Although thrombosis can be a complication of replantation, routine anticoagulant management is not recommended due to limited scientific evidence, and should be used only with justification [7, 10]. Occasionally, the biggest problem is old intolerance or sensory disturbance [7, 9, 10, 12], as occurred in the presented case.

This report concerns only one clinical case. It would therefore be advisable to attempt to increase the number of distal phalanx sewing attempts in non-specialized surgical centres to assess the real risk or success of such surgery.

CONCLUSIONS

Improved survival and better long-term outcomes of replanted fingers depend on the rapid response of the treatment team at each stage of treatment, commitment of the team members, and self-involvement of the patient.

The success of surgery without bone arthrodesis, vascular reconstruction, and access to professional staff and equipment, may motivate medical teams to increase attempts at distal phalangeal replantation, a procedure that can be performed in local clinics and emergency departments by less experienced surgeons.

Early and comprehensive rehabilitation treatment influences a better functional outcome of the replanted finger.

REFERENCES

1. Mucci N, Traversini V, Lulli LG, Baldassarre A, Galea RP, Arcangeli G. Upper Limb's Injuries in Agriculture: A Systematic Review. *Int J Environ Res Public Health*. 2020;17(12):4501.
2. Reid DBC, Shah KN, Eltorai AEM, et al. Epidemiology of finger amputations in the united states from 1997 to 2016. *J Hand Surg Glob Online*. 2019;1:45–51.
3. Yaffe MA, Kaplan FT. Agricultural Injuries to the Hand and Upper Extremity. *J Am Academy Orthopaedic Surg*. 2014;22(10):605–613.
4. Neinstein RM, Dvali LT, Le S, Anastakis DJ. Complete digital amputations undergoing replantation surgery: a 10-year retrospective study. *Hand (N Y)*. 2012;7(3):263–266.
5. Chen J, Huang Y, Liu Z. Analysis of the factors affecting survival in digital replantation. *Int J Clin Exp Med*. 2017;10(3):5445–5448.
6. Yu H, Wei L, Liang B, Wang J, Yang Y. Nonsurgical factors of digital replantation and survival rate A metaanalysis. *Iniadn J Orthop*. 2015;49(3):265–271.
7. Atkins SE, Wintertona RIS, Kay SP. (v) Upper limb amputations: Where, when and how to replant. Mini-symposium: Hand trauma. 2008;22(1):31–41.
8. Prsic A, Friedrich JB. Postoperative management and rehabilitation of the replanted or revascularized digit. *Hand Clin*. 2019;35(2):221–229.
9. Ugurlar M, Kabakas F, Purisa H, Sezer I, Celikdelen P, Ozcelik IB. Rehabilitation after successful finger replantation. *North Clin Istanbul*. 2016;3(1):22–26.
10. Barbato B, Salsac AV. Finger and thumb replantation: From biomechanics to practical surgical applications. *Hand Surg Rehabil*. 2020;39(2):77–91.
11. Li YS, Chen CY, Yang SW, Tarng YW. Cross-finger subdermal pocketplasty as a salvage procedure for thumb tip replantation without vescular anastomosis: a case report. *J Int Med Res*. 2018;46(9):3717–3723.
12. Charpentier K, Loisel F, Menu G, Feuvrier D, Obert L, Pluvy I. Long-term functional results of digital replantation: A survey of 28 patients. *Hand Surg Rehabil*. 2019;38(6):375–380.
13. Pasek J, Pasek T, Cieślak G, Sieroń A. Physical medicine after limb transplantation. Therapeutic effects of physical procedures in the treatment of limb transplantation after cut-off by a threshing machine – Case report. *Ann Agric Environ Med*. 2018;25(2):241–243. doi:10.26444/aaem/75112