



A case of exudative pleuritis caused by *Staphylococcus warneri*

Mateusz Szymański^{1,2,A-F}, Małgorzata Maria Skiba^{1,B-F}, Małgorzata Piasecka^{1,B-C,E-F}

¹ Stefan Cardinal Wyszyński District Specialist Hospital, Lublin, Poland

² Department of Human Anatomy, Medical University, Lublin, Poland

A – Research concept and design, B – Collection and/or assembly of data, C – Data analysis and interpretation, D – Writing the article, E – Critical revision of the article, F – Final approval of the article

Szymański M, Skiba MM, Piasecka M. A case of exudative pleuritis caused by *Staphylococcus warneri*. Ann Agric Environ Med. doi: 10.26444/aaem/174906

Abstract

This paper discusses the case of a patient with exudative bacterial pneumonia caused by *Staphylococcus warneri*. The patient had been abusing alcohol and nicotine for several decades, which should be considered an immunosuppressive factor. *Staphylococcus warneri* is part of the skin microbiome, but can also be a pathogenic agent in certain circumstances. Pleural fluid is an unusual site of isolation for the staphylococcus described. The literature contains case reports of arthritis, endocarditis, urinary tract infection or infection associated with continuous ambulatory peritoneal dialysis caused by *Staphylococcus warneri*. With the development of medicine, the phenomenon of immunosuppression is becoming more common, posing the threat of an increase in invasive infections caused by coagulase-negative staphylococci. In addition, an overly liberal use of antibiotics may contribute to the generation of multidrug resistance in these micro-organisms.

Key words

immunosuppression, coagulase-negative, *Staphylococcus warneri*, exudative pneumonia, Pleural fluid

INTRODUCTION

As long ago as 1891, the American pathologist William H. Welch, in his work 'Conditions underlying the infection of wounds', pointed out the obvious fact that bacteria are responsible for wound infection. He also described *Staphylococcus epidermidis albus*, a coagulase-negative staphylococcus, as a bacterium that almost constantly colonises human skin, but also presented it as a potential pathogen that could be responsible for wound infection [1, 2]. With the continuous development of medicine, including the increasing use of invasive techniques, the importance of coagulase-negative staphylococci is increasing significantly [3, 4, 5, 6, 7]. Shin JH et al. in their study analysed coagulase-negative staphylococci causing peritonitis in peritoneal haemodialysis patients in an outpatient setting. Among the 51 isolates studied by sequencing, *Staphylococcus epidermidis* was the most frequently found (66.7%), followed by *Staphylococcus haemolyticus* (11.8%), *Staphylococcus warneri* (7.8%), *S. caprae* (5.9%), *S. capitis* (3.9%) and *S. Pasteuri* (2.0%) [8]. Bertelloni F. et al. presented the results of a study that demonstrates that coagulase-negative staphylococci, including those that were multidrug-resistant, can be transmitted by house flies (*Musca domestica*) [9]. Undoubtedly, this is another factor favouring the spread of these pathogens and, in combination with the increasingly common phenomenon of immunosuppression, translates into an increase in invasive infections caused by coagulase-negative staphylococci. Such invasive infections caused by coagulase-negative staphylococci typically proceed less aggressively than those caused by *Staphylococcus aureus*, and are more prolonged over time. However, in recent years, they have become of increasing clinical importance [10, 11, 12, 13, 14].

CASE REPORT

A 64-year-old female patient, with a history of alcohol abuse for several decades and nicotine (approx. 40 pack-years), previously diagnosed with heart failure and chronic obstructive pulmonary disease (COPD), and consistent non-adherence to the recommended treatment, was brought to the Hospital Emergency Department due to increasing dyspnoea and consciousness disturbances. Due to suspected exacerbation of COPD and exacerbation of heart failure, the patient was admitted to the Department of Internal Medicine. Treatment included dehydrating (Furosemideum, Spironol), mucolytic, bronchodilatation drugs, empirical antibiotic therapy (ceftriaxone 1g/day, dose reduction explained by reduced renal clearance; eGFR approx. 30 ml/min/1.73m²), and passive oxygen therapy. Empirical antibiotic therapy was initiated in accordance with current recommendations for the treatment of severe exacerbation of chronic obstructive pulmonary disease with concomitant cardiac disease [15].

During the first few days of stay, an initial stabilisation and then a partial improvement of the patient's general condition was achieved. The chest X-ray mentioned, in addition to an enlarged cardiac silhouette, suggested the possible presence of fluid in the right pleural cavity. After a period of improvement and stabilisation of the patient's condition, a gradual deterioration was observed from day 10 onwards, with a four-fold increase in oxygen requirements and the need for catecholamines due to hypotonia. At that time, the patient was febrile. Laboratory tests showed a significant increase in leukocytes, neutrophils, acute phase protein (CRP). Due to increasing respiratory failure and developing respiratory acidosis, hypercapnia and hypoxaemia, accompanied by impaired consciousness, the decision was made to sedate, intubate and ventilate the patient. After anaesthesiological consultation, the patient was transferred to the Intensive Care Unit. Sepsis and septic shock were

✉ Address for correspondence: Małgorzata Maria Skiba, Stefan Cardinal Wyszyński District Specialist Hospital, Lublin, Poland
E-mail: skibamalgorzata@op.pl

Received: 31.08.2023; accepted: 07.11.2023; first published: 17.11.2023

ruled out, based on microbiological tests (negative results of repeated blood cultures) and evaluation of the dynamics of changes in inflammatory parameters (procalcitonin not exceeding the accepted laboratory standard, normal lactic acid concentration). An ultrasound of the pleural cavities confirmed a significant amount of fluid in the right pleural cavity (mantle thickness of approx. 7 cm). Under aseptic conditions, the right pleural cavity was punctured and 1,500 ml of cloudy fluid was decompressed, part of which was sent for microbiological examination).

The following day, the right pleural cavity fluid was punctured again – 700 ml of also cloudy fluid was decompressed, and a sample sent for microbiological analysis. Both samplings showed an increase in cloxacillin-sensitive *Staphylococcus warneri* (MSCoN). Therefore, a daily dose of 12 g of intravenous cloxacillin was used in therapy. Already on the third day of therapy, a significant improvement in the patient's ventilation parameters and general condition was observed, with a decrease in inflammatory parameters, such as IL-6, CRP, leukocytes, neutrophils. On this basis, coagulase-negative *Staphylococcus warneri* was recognised as the pathogen. It was the etiological agent of bacterial exudative pleuritis.

DISCUSSION

Heart failure was the cause of the pleural fluid. Alcoholism was an immunosuppressive factor that played a key role in the translocation of a commensal bacterium such as *Staphylococcus warneri* into the pleural fluid. The defence mechanisms of the patient's body had broken down and the microorganism caused infection of the pleural fluid. Undoubtedly, cases such as that described in this article are extremely valuable, as they provide new information about the potential risks arising not only from *Staphylococcus warneri* infections, but also from infections caused by other commensal microorganisms.

Staphylococcus warneri is a gram-positive coagulase-negative coccus. It is a component of the skin microbiome, but in certain situations it can also be a pathogenic agent. On agar medium with 5% sheep blood, it usually forms smooth, shiny and opaque grey-white colonies, sometimes with a yellow to light orange tinge. It shows no resistance to novobiocin and gives a negative oxidase test. It is isolated from fermented foods, and has been also isolated among animals, e.g. in dogs, cats, goats, horses, monkeys, pigs, rodents and sheep, as well as in fish food [2, 16, 17, 18, 19, 20, 21]. In humans, the most common sites of isolation are the skin of the lower limbs, arms, head and nostrils. Reports of invasive infections caused by *Staphylococcus warneri* are relatively rare. In humans, so far it has been isolated only as the aetiological agent of arthritis, infection associated with continuous ambulatory peritoneal dialysis, or infection associated with prosthetic bones and joints [22, 23]. *Staphylococcus warneri* has also been the aetiological agent of infective endocarditis in drug users [24] as well as immunocompetent individuals [25, 26, 27, 28, 29]. Reports of symptomatic urinary tract infection caused by this pathogen are available in the literature [30].

Staphylococcus warneri colonises the skin of the babies already in the first weeks of postnatal life [31, 32]. Heilmann et al. distinguished three main factors contributing to

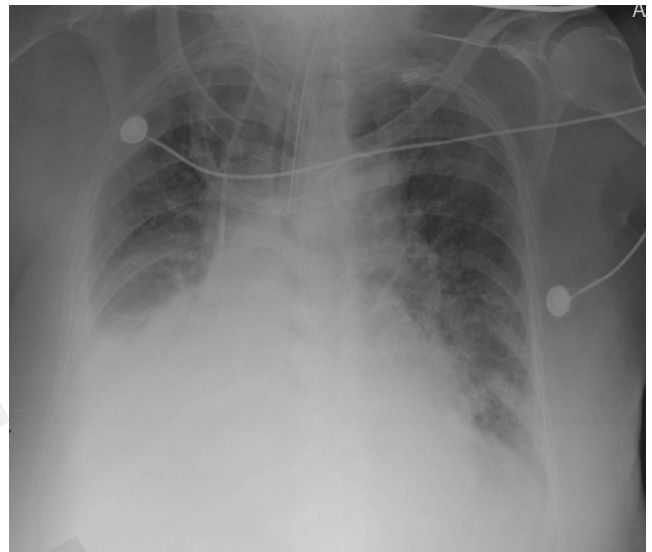


Figure 1. Chest radiographs with visible fluid in the right costodiaphragmatic recess. X-ray taken on day of admission to the ICU

the increased clinical significance of coagulase-negative staphylococci. These include a weakened immune system/immunosuppression, damage to the natural barrier such as the skin or mucous membranes and the presence of foreign bodies or implants. At the same time, the authors emphasise that the widespread and overly liberal use of antibiotics may influence multidrug resistance of these microorganisms [33, 34, 35, 36].

It should be noted that in the initial stage of treatment the patient was receiving ceftriaxone, which exhibits activity against MSCoN strains. There could have been several reasons for the failure of this therapy in the described patient. Firstly, among the third-generation cephalosporins, ceftriaxone is characterised by a high degree of binding with plasma proteins (80–90%), and the steady state of the antibiotic in plasma is established rather late, i.e. even 48–72 hours after the implementation of antibiotic therapy. Secondly, the dose of ceftriaxone was reduced, although it is not recommended to reduce the typical (2 g) dose of ceftriaxone in cases of reduced renal clearance. Although the reduction of the ceftriaxone dose in the present case did not affect the induction of resistance to beta-lactam antibiotics, it is likely that the drug concentration in the pleural fluid did not reach the threshold for bactericidal activity. It should be noted that the pharmacokinetics of ceftriaxone are not linear, and most pharmacokinetic parameters (with the exception of elimination half-life) are dependent on the dose of the antibiotic in serum. This is due to the high degree of binding of the drug to plasma proteins. In other words, a certain time is needed for the saturation of plasma proteins to occur (48–72hrs), and then only after a steady state has been established is the drug activity higher than at the start of treatment. The effect of beta-lactam antibiotics, and therefore of ceftriaxone, depends on the drug not binding to plasma proteins, the concentration of which should exceed the minimum inhibitory concentration for the pathogen in question (MIC), this relationship is referred to as %T>MIC. Therefore, for some beta-lactam antibiotics (e.g. meropenem, piperacillin with tazobactam, ceftazidime or cefepime), it is possible to use extended infusions, which significantly improves treatment outcomes by improving the

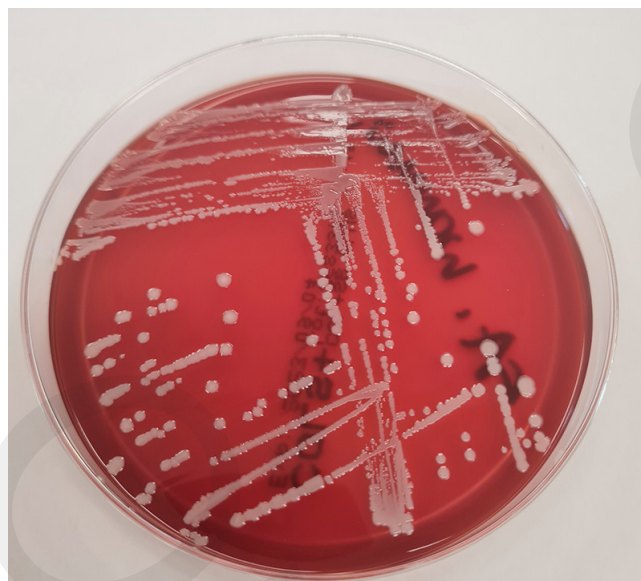


Figure 2. *Staphylococcus warneri* colonies on agar containing 5% sheep blood. Culture of exudate fluid collected during thoracentesis

pharmacokinetic-pharmacodynamic profile.

A key factor in deciding whether a beta-lactam antibiotic can be administered as a prolonged infusion is its stability in solution. This information should be included in the summary of product characteristics. Interestingly, in American and Polish recommendations, prolonged infusions are allowed for penicillin, whereas in the characteristics of preparations currently available on the Polish market, there is no clear annotation as to how long a dissolved antibiotic is stable. This creates some difficulties in the context of the correct use of prolonged infusions for penicillin. It is also worth mentioning that penicillin remains the most appropriate choice for streptococcal and pneumococcal infections, and under Polish conditions the sensitivity of streptococci to penicillin is 100%. It is the only antibiotic that has a proven record of preventing the development of rheumatic fever as a late complication of streptococcal tonsillitis. The excellent pharmacokinetic and pharmacodynamic profile of penicillin makes it suitable for successful use in infections not only of the lower and upper respiratory tract, but also of the bloodstream, meninges, bones and joints.

Very often, untreated or ineffectively treated infections can lead to sepsis, which may progress to septic shock, and ultimately result in the patient's death. Therefore, meticulous diagnostics and clinical vigilance are of utmost importance as they contribute to early diagnosis and the initiation of targeted treatment. In the described case, due to the state of immunosuppression, the risk of therapy failure due to a delay in commencing targeted antibiotic therapy was significant.

CONCLUSION

It should be emphasised once again that with the advancement of medicine, new threats now have to be faced. In addition to the rapidly increasing number of multi-drug resistant bacteria, attention should be given to the fact that commensal bacteria can also pose a significant clinical problem in certain situations, as illustrated in the described case. Due to the increasing number of immunocompromised patients,

there is a growing risk of an increase in invasive coagulase-negative staphylococcal infections such as *Staphylococcus warneri*. The location of the pathogen may be atypical, as in the case described – in fluid collected from the pleural cavities. It is essential to make careful antibiotic choices in the treatment of these infections to prevent the development of multidrug resistance in bacteria, and to follow the principles of rational antibiotic therapy, considering not only the choice of the right antibiotic, but also its dosage, route and time of administration, as well as its pharmacokinetic and pharmacodynamic profile.

REFERENCES

1. Welch WH. Conditions underlying the infection of wounds. *Am J Med Sci.* 1891;439–465.
2. Qi S, Gao B, Zhu S. A Fungal Defensin Inhibiting Bacterial Cell-Wall Biosynthesis with Non-Hemolysis and Serum Stability. *J Fungi.* 2022;8(2):174. <https://doi.org/10.3390/jof8020174>
3. Kloos WE, Bannerman TL. Update on clinical significance of coagulase-negative staphylococci. *Clin Microbiol Rev.* 1994;7(1):117–140. <https://doi.org/10.1128/cmr.7.1.117>
4. Heilmann C, Ziebuhr W, Becker K. Are coagulase-negative staphylococci virulent? *Clin Microbiol Infect.* 2019;25(9):1071–1080. <https://doi.org/10.1016/j.cmi.2018.11.012>
5. Paranthaman K, Wilson A, Verlander N, et al. Trends in coagulase-negative staphylococci (CoNS), England, 2010–2021. *Access Microbiol.* 2023;5(6):acmi000491.v3. <https://doi.org/10.1099/acmi.0.000491.v1>
6. França A. The Role of Coagulase-Negative Staphylococci Biofilms on Late-Onset Sepsis: Current Challenges and Emerging Diagnostics and Therapies. *Antibiotics.* 2023;12(3):554. <https://doi.org/10.3390/antibiotics12030554>
7. Pinheiro-Hubinger L, Moraes Riboli DF, Abraão LM, et al. Coagulase-Negative Staphylococci Clones Are Widely Distributed in the Hospital and Community. *Pathogens.* 2021;10(7):792. <https://doi.org/10.3390/pathogens10070792>
8. Shin JH, Kim SH, Jeong HS, et al. Identification of coagulase-negative staphylococci isolated from continuous ambulatory peritoneal dialysis fluid using 16S ribosomal RNA, tuf, and SodA gene sequencing. *Perit Dial Int.* 2011;31(3):340–346. <https://doi.org/10.3747/pdi.2010.00073>
9. Bertelloni F, Cagnoli G, Bresciani F, et al. Antimicrobial Resistant Coagulase-Negative Staphylococci Carried by House Flies (*Musca domestica*) Captured in Swine and Poultry Farms. *Antibiotics (Basel).* 2023;12(4):636. <https://doi.org/10.3390/antibiotics12040636>
10. Becker K, Both A, Weißelberg S, et al. Emergence of coagulase-negative staphylococci. *Expert Rev Anti Infect Ther.* 2020;18(4):349–366. <https://doi.org/10.1080/14787210.2020.1730813>
11. Michels R, Last K, Becker SL, et al. Update on Coagulase-Negative Staphylococci-What the Clinician Should Know. *Microorganisms.* 2021;9(4):830. <https://doi.org/10.3390/microorganisms9040830>
12. Ansari F, Banerjee T, Kumar A, et al. Coagulase-Negative Staphylococci in Neonatal Blood: How Concerning? *J Lab Physicians.* 2023;15(1):126–130. <https://doi.org/10.1055/s-0042-1757411>
13. Popa-Fotea NM, Scafa-Udriste A, Iulia G, et al. Increasing clinical impact and microbiological difficulties in diagnosing coagulase-negative staphylococci in infective endocarditis – a review starting from a series of cases. *Curr Med Res Opin.* 2022;38(12):2077–2083. <https://doi.org/10.1080/03007995.2022.2122673>
14. Yamamoto J, Endo A, Sugawara H, et al. Native Valve Endocarditis due to *Staphylococcus warneri* Developing in a Patient with Type 1 Diabetes. *Intern Med.* 2020;59(18):2269–2274. <https://doi.org/10.2169/internalmedicine.4661-20>
15. Żukowska A, Hryniewicz W, editors. Recommendations for diagnosis, therapy and antibiotic prophylaxis of infections in hospital – 2020, Material for therapeutic committees and antibiotic therapy teams. National Medicines Institute 2020. [in Polish]
16. Kern A, Perreten V. Clinical and molecular features of methicillin-resistant, coagulase-negative staphylococci of pets and horses. *J Antimicrob Chemother.* 2013;68(6):1256–1266. <https://doi.org/10.1093/jac/dkt020>
17. de Oliveira RP, da Silva JG, Aragão BB, et al. Diversity and emergence of multi-resistant *Staphylococcus* spp. isolated from subclinical mastitis in

- cows in of the state of Piauí, Brazil. *Braz J Microbiol.* 2022;53:2215–2222. <https://doi.org/10.1007/s42770-022-00822-1>
18. Regecová I, Výrostková J, Zigo F, et al. Detection of Resistant and Enterotoxigenic Strains of *Staphylococcus warneri* Isolated from Food of Animal Origin. *Foods.* 2022;11(10):1496. <https://doi.org/10.3390/foods11101496>
 19. Wang M, Wang C, Yang C, et al. Effects of *Lactobacillus plantarum* C7 and *Staphylococcus warneri* S6 on flavor quality and bacterial diversity of fermented meat rice, a traditional Chinese food. *Food Res Int.* 2021; 150(Pt A):110745. <https://doi.org/10.1016/j.foodres.2021.110745>
 20. Lawal OU, Adekanmbi AO, Adelowo OO. Occurrence of methicillin-resistant staphylococci in the pig-production chain in Ibadan, Nigeria. *Onderstepoort J Vet Res.* 2021;88(1):e1–e4. <https://doi.org/10.4102/ojvr.v88i1.1959>
 21. Abdel-Moein KA, Zaher HM. The Nasal Carriage of Coagulase-Negative Staphylococci Among Animals and Its Public Health Implication. *Vector-Borne Zoonotic Dis.* 2020;20(12):897–902. <http://doi.org/10.1089/vbz.2020.2656>
 22. Becker K, Heilmann C, Peters G. Coagulase-negative staphylococci. *Clin Microbiol Rev.* 2014;27(4):870–926. <https://doi.org/10.1128/cmr.00109-13>
 23. Şimşek F, Yevgi R, Yalçın A. Primary Bacterial Ventriculitis caused by *Staphylococcus warneri*. *Rev Soc Bras Med Trop.* 2023;56:e0631. <https://doi.org/10.1590/0037-8682-0631-2022>
 24. Stöllberger C, Wechsler-Fördös A, Geppert F, et al. *Staphylococcus warneri* endocarditis after implantation of a lumbar disc prosthesis in an immunocompetent patient. *J Infect.* 2006;52(1):15–18. <https://doi.org/10.1016/j.jinf.2005.04.016>
 25. Diaconu R, Golubeanu E, Constantin A, et al. Native valve endocarditis with *Staphylococcus warneri*. *BMJ Case Rep.* 2019;12(6):e229546. <http://dx.doi.org/10.1136/bcr-2019-229546>
 26. Alawad MJ, Ali GA, Goravey W. Underrecognized pathogen; *Staphylococcus warneri*-associated native mitral valve endocarditis in an immunocompetent host: A case report and literature review. *Clin Case Rep.* 2022;10(4):e05591. <https://doi.org/10.1002/ccr3.5591>
 27. Gelman R, Potruch A, Oster Y, et al. Native aortic valve *Staphylococcus warneri* endocarditis after COVID-19 infection: a case report and a review of literature. *APMIS.* 2022;130(5):270–275. <https://doi.org/10.1111/apm.13217>
 28. Kurihara I, Yoshida K, Fukuchi T, et al. Native mitral valve infective endocarditis caused by *Staphylococcus warneri*: A case-based review. *Clin Case Rep.* 2021;9:e0476. <https://doi.org/10.1002/ccr3.4476>
 29. Albert NM, Bena JF, Ciudad C, et al. Contamination of reusable electroencephalography electrodes: A multicenter study. *Am J Infect Control.* 2018;46(12):1360–1364. <https://doi.org/10.1016/j.ajic.2018.05.021>
 30. Kanuparth A, Challa T, Meegada S, et al. *Staphylococcus warneri*: Skin Commensal and a Rare Cause of Urinary Tract Infection. *Cureus.* 2020;12(5):e8337. <https://doi.org/10.7759/cureus.8337>
 31. Björkqvist M, Liljedahl M, Zimmermann J, et al. Colonization pattern of coagulase-negative staphylococci in preterm neonates and the relation to bacteremia. *Eur J Clin Microbiol Infect Dis.* 2010;29(9):1085–1093. <https://doi.org/10.1007/s10096-010-0966-3>
 32. Battisti O, Mitchison R, Davies PA. Changing blood culture isolates in a referral neonatal intensive care unit. *Arch Dis Child.* 1981;56:775–778. <http://dx.doi.org/10.1136/adc.56.10.775>
 33. Heilmann C, Ziebuhr W, Becker K. Are coagulase-negative staphylococci virulent? *Clin Microbiol Infect.* 2019;25(9):1071–1080. <https://doi.org/10.1016/j.cmi.2018.11.012>
 34. Rouard C, Doucet-Populaire F, Guillet-Caruba C, et al. Deletion of One 23S rRNA Gene (rrl) Copy Contributes to the Development of Linezolid Resistance in *Staphylococcus warneri*. *Antimicrob Agents Chemother.* 2018;62(11):e01139–18. <https://doi.org/10.1128/aac.01139-18>
 35. Colombo APV, do Souto RM, Araújo LL, et al. Antimicrobial resistance and virulence of subgingival staphylococci isolated from periodontal health and diseases. *Sci Rep* 2023; 13(1):11613 (2023). <https://doi.org/10.1038/s41598-023-38599-4>
 36. Friedrich AW. Control of hospital acquired infections and antimicrobial resistance in Europe: the way to go. *Wien Med Wochenschr.* 2019; 169(1):25–30. <https://doi.org/10.1007/s10354-018-0676-5>