



Lipoid pneumonia induced by aspiration of liquid paraffin

Konrad Siebert^{1,A-F}, Ewa Jassem^{1,C,E-F}, Maria Porzezińska^{1,A,C}, Małgorzata Jelitto^{2,B-E},
Weronika Bernard^{2,C,E}

¹ Department of Pneumology and Allergology, University Clinical Centre, Medical University, Gdańsk, Poland

² Second Department of Radiology, Clinical Centre, Medical University, Gdańsk, Poland

A – Research concept and design, B – Collection and/or assembly of data, C – Data analysis and interpretation, D – Writing the article, E – Critical revision of the article, F – Final approval of the article

Siebert K, Jassem E, Porzezińska M, Jelitto M, Bernard W. Lipoid pneumonia induced by aspiration of liquid paraffin. *Ann Agric Environ Med*. doi: 10.26444/aaem/168783

Abstract

Introduction. This case report describes a case of exogenous lipoid pneumonia (ELP) resulting from the inhalation of a lipoid substance. Lipoid pneumonia, also known as cholesterol pneumonia or golden pneumonia, is an uncommon inflammatory lung disease characterized by the presence of lipid-laden macrophages in the alveolar walls and lung interstitial tissue. Exogenous lipoid pneumonia occurs when substances containing lipids enter the airways through aspiration or inhalation, triggering an inflammatory response.

Case Report. The patient in this case study was an 83-year-old woman with hypertension and diabetes mellitus who had been using paraffin oil as a mouthwash for an extended period. The diagnosis of exogenous lipoid pneumonia was established based on the patient's history of exposure to liquid paraffin oil, typical radiological findings, and histopathological examination.

Key words

rheumatoid arthritis, electronic cigarettes, liquid paraffin, Lipoid pneumonia, interstitial pulmonary disease

INTRODUCTION

Lipoid pneumonia, also known as cholesterol pneumonia or golden pneumonia, is an uncommon inflammatory lung disease characterized by the presence of lipid-laden macrophages in the alveolar walls and interstitial tissue of the lungs [1]. Exogenous lipoid pneumonia (ELP) occurs when substances containing lipids are aspirated or inhaled, leading to an inflammatory reaction. Diagnosing ELP can be challenging due to its non-specific and diverse clinical manifestations. As ELP is a rare condition with no specific clinical or imaging features, its course remains poorly understood. While cytological tests such as bronchoalveolar lavage or fine-needle aspiration may be performed in ELP patients, the definitive diagnosis often relies on histological examination and high-resolution computed tomography [2, 3].

CASE REPORT

An 83-year-old female patient with dyspnea (mMRC-2), productive cough, hypertension, and obesity was admitted to the Department of Pulmonology.

The mMRC scale, also known as the Modified Medical Research Council scale, is a tool used to assess the severity of breathlessness experienced by individuals with respiratory conditions. The scale consists of 5 levels ranging from 0–4, with 0 indicating no breathlessness, and 4 representing severe breathlessness even during minimal physical activity.

Over the past 24 months, the patient's physical condition had significantly deteriorated. Initial evaluation indicated a suspicion of non-specific interstitial fibrosis. Spirometry results after salbutamol inhalation showed a moderate decline in FEV1 (77%), VC (81%), and FEV1%VC (72.06%). However, the single-breath diffusing capacity of the lung for CO (DLCO SB) was severely impaired, measuring 28%.

A chest computed tomography (CT) scan revealed centrilobular nodules accompanied by surrounding ground-glass opacities and consolidations. The affected areas were primarily located in the lower lobes of the lungs, including segment 10 of the left lower lobe, segments 9 and 10 of the right lower lobe, and segment 3 of the right upper lobe. Composite CT images of the chest demonstrated bilateral consolidation, predominantly in the lower lobes of the right lung. These consolidations exhibited low density, measuring between -100 and -30 Hounsfield units, without enhancement of the lesions (Fig. 1 and 2).

Bronchofiberscopy revealed anthracosis (black pigment discolouration) in the left upper lobe bronchus and bronchi leading to the basal segments. The basal segments of the bronchi appeared narrow and deformed. Bronchoalveolar lavage fluid collected from the right lower lobe appeared cloudy, and cytospin analysis of the specimen revealed numerous lipid-laden macrophages that stained positive for fat.

Subsequently, a transthoracic biopsy was performed, and histological examination demonstrated lipid-laden macrophages in the alveolar walls, interstitial pulmonary fibrosis, multinucleated giant cells, and scattered inflammatory cells including lymphocytes, plasma cells, neutrophils, and rare eosinophils. Cytological analysis revealed multiple intra-alveolar macrophages containing distinct intracytoplasmic vacuoles of varying sizes, along with occasional bi- or multi-nucleated cells.

✉ Address for correspondence: Konrad Siebert, Department of Pneumology and Allergology, Medical University, Dębinki 7, 80–211 Gdańsk, Poland
E-mail: siebert.konrad@gmail.com

Received: 28.02.2023; accepted: 24.06.2023; first published: 20.07.2023

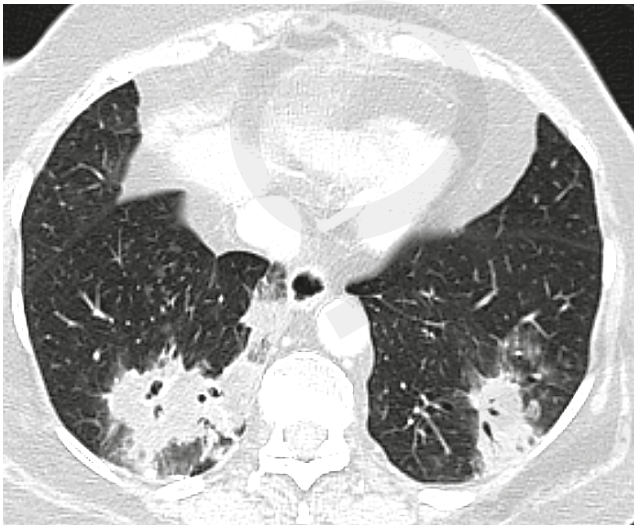

Figure 1. Bilateral lung consolidations surrounded by ground-glass opacity

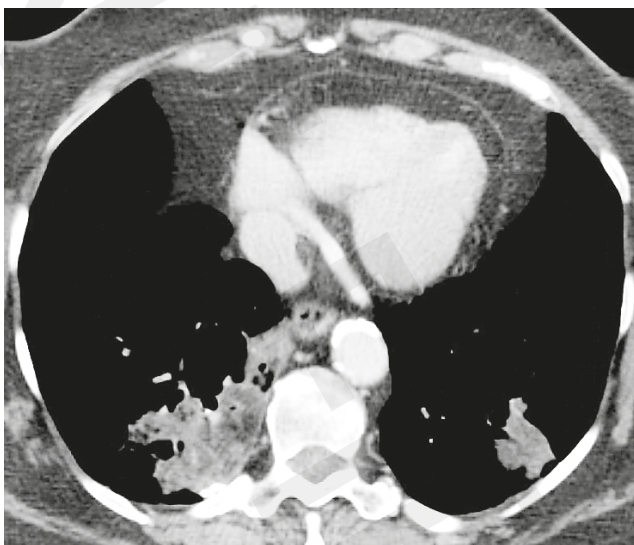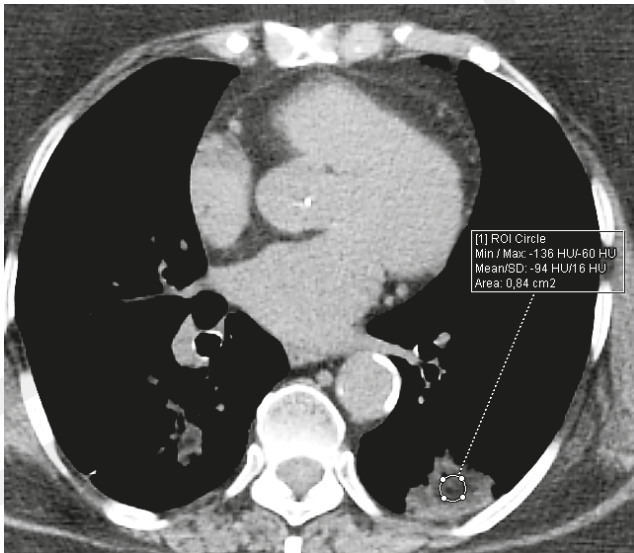


Figure 2 and 3. Areas within the consolidations showing low density (resembling fatty tissue)

Additional history obtained after completing the diagnostic tests revealed that the patient had been inhaling liquid paraffin oil for several years to manage xerostomia. Consequently, the diagnosis of exogenous lipoid pneumonia (ELP) was confirmed.

One year after discontinuing the use of liquid paraffin oil, a teleconsultation was conducted with the patient. During the consultation, a comprehensive range of strategies for managing xerostomia was presented. The patient was informed about the potential use of medications like pilocarpine, the importance of maintaining hydration through regular water intake and using a humidifier. Additionally, relief from xerostomia symptoms could be obtained through saliva substitutes, artificial saliva products, and stimulating saliva flow with sugar-free chewing gum or sweets. The patient was advised to avoid irritants like tobacco and caffeine. Overall, there was an improvement in the patient's condition, with no new symptoms reported and a reduction in cough.

DISCUSSION

This case report focused on exogenous lipoid pneumonia (ELP) caused by the inhalation of a lipoid substance. The diagnosis of ELP relied on a combination of factors, including a history of exposure to liquid paraffin oil, characteristic radiological findings, and histopathological examination.

The initial histopathological examination of ELP was documented by Laughlen as a case report in 1925 [4]. This diagnostic tool continues to play a crucial role in identifying LP. Chest computed tomography (CT) scans can reveal diverse patterns such as consolidations, ground-glass opacities (GGO), 'crazy-paving' patterns (thickened interlobular septa superimposed on GGO resembling irregular paving stones), interstitial thickening, or masses. Mayo Clinic researchers described 34 cases of ELP and acknowledged the diagnostic challenges due to non-specific CT findings [3, 5]. However, high-resolution CT, which can detect low-density areas (measuring from -100 to -30 Hounsfield units), is considered the most effective imaging modality for diagnosing LP [6, 7]. Additionally, the presence of large vacuoles in macrophages seen in cytological specimens may raise suspicion of ELP [8, 9].

In the presented case, the initial suspicion of ELP based on CT images was not confirmed until the completion of diagnostic tests and the identification of histological evidence showing lipid-laden macrophages, at which point the patient admitted to using the oil for years. ELP is commonly associated with the aspiration of mineral oil, but vegetable and animal oils, as well as other inhaled substances like nasal ointments/drops and occupation-related agents, can also cause the disease [9].

Electronic cigarettes (e-cigs), which have become increasingly popular, have been reported to cause lung injuries, including acute eosinophilic pneumonia (AEP) and lipoid pneumonia, although such cases are rare [10]. When evaluating e-cigarette users with atypical pneumonia, bronchoalveolar lavage (BAL) and biopsy are necessary to confirm the presence or absence of lipid-laden macrophages [10].

Endogenous lipoid pneumonia is another uncommon inflammatory pulmonary disease caused by endogenous lipids. Currently, there is no established treatment for this

condition. This case report presents the first case of endogenous lipoid pneumonia, presenting as lung consolidation, which was associated with rheumatoid arthritis (RA). RA is a systemic auto-immune disease that can affect various organs, including the lungs. Patients with RA may develop a range of pulmonary diseases, such as airway diseases, interstitial lung diseases, and pleuritis. When lung consolidation is detected in the presence of active rheumatic disease, lipoid pneumonia should be considered as a potential diagnosis [11].

CONCLUSION

Diagnosis of ELP can be challenging due to non-specific clinical findings, and definitive diagnosis often relies on histology and high-resolution computed tomography (CT). In the presented case, an 83-year-old woman with a history of liquid paraffin oil inhalation was diagnosed with ELP, based on radiological and histopathological findings. CT scans showed characteristic features, such as centrilobular nodules, ground-glass opacities, and consolidations with low-density areas. Exposure history is crucial for accurate diagnosis, and CT imaging is increasingly important in the diagnostic process. Prompt recognition and understanding of ELP are essential for timely management of this rare condition.

REFERENCES

1. Agudel CW, Samaha G, Garcia-Arcos I. Alveolar lipids in pulmonary disease. A review. *Lipids Health Dis.* 2020;19(1):122. <https://doi.org/10.1186/s12944-020-01278-8>
2. Bartosiewicz M, Zimna K, Lewandowska K, et al. Exogenous lipoid pneumonia induced by nasal instillation of paraffin oil. *Adv Respir Med.* 2019;87(6):254–257. <https://doi.org/10.5603/ARM.2019.0063>.
3. Samhoury BF, Tandon YK, Hartman TE, et al. Presenting Clinicoradiologic Features, Causes, and Clinical Course of Exogenous Lipoid Pneumonia in Adults. *Chest.* 2021;160(2):624–632. <https://doi.org/10.1016/j.chest.2021.02.037>.
4. Laughlen GF. Studies on pneumonia following nasopharyngeal injections of oil. *Am J Pathol.* 1925;1(4):407–414.
5. Baron SE, Haramati LB, Rivera VT. Radiological and clinical findings in acute and chronic exogenous lipoid pneumonia. *J Thorac Imaging.* 2003;18(4):217–224. <https://doi.org/10.1097/00005382-200310000-00002>.
6. Maoqing G, Jianguo L, Bo J. Exogenous lipid pneumonia in old people caused by aspiration: Two case reports and literature review. *Respir Med Case Rep.* 2019;27:100850. <https://doi.org/10.1016/j.rmcr.2019.100850>
7. Cozzi D, Cavigli E, Moroni C, et al. Ground-glass opacity (GGO): a review of the differential diagnosis in the era of COVID-19. *Jpn J Radiol.* 2021;39(8):721–732. <https://doi.org/10.1007/s11604-021-01120-w>.
8. Woge MJ, Ryu JH, Bartholmai BJ, et al. Cicatricial organizing pneumonia: a clinicopathologic and radiologic study on a cohort diagnosed by surgical lung biopsy at a single institution. *Hum Pathol.* 2020;101:58–63. <https://doi.org/10.1016/j.humpath.2020.04.013>.
9. Sung S, Tazelaar HD, John P, et al. Adult exogenous lipoid pneumonia: A rare and underrecognized entity in cytology – A case series. *Cyto J.* 2018;15:17. https://doi.org/10.4103/cytojournal.cytojournal_29_17.
10. Itoh M, Aoshiba K, Herai Y, et al. Lung injury associated with electronic cigarettes inhalation diagnosed by transbronchial lung biopsy. *Respirology Case Reports Open Access* 2018; 6(1): e00282, <https://doi.org/10.1002/rcr2.282>.
11. Morita H, Arai S, Kurasawa K, et al. Intensive immunosuppressive therapy for endogenous lipoid pneumonia associated with rheumatoid arthritis. *Modern Rheumatol.* 2018;28(6):1044–1048. <https://doi.org/10.1080/14397595.2016.1193270>.