



Giant haematoma of the posterior compartment of thigh in a patient with coronavirus disease 19 pneumonia and pulmonary embolism – Case Report

Anna Grzywa-Celińska^{1,A-F}✉, Justyna Emeryk-Maksymiuk^{2,A-E}, Piotr Tarkowski^{3,A-E}, Adam Krusiński^{1,A-E}, Katarzyna Redestowicz^{1,A-D}, Jan Siwiec^{1,A-E}, Dorota Suszek^{4,A-D}

¹ Chair and Department of Pneumology, Oncology and Allergology, Medical University, Lublin, Poland

² Chair of Internal Medicine and Department of Internal Medicine in Nursing, Medical University, Lublin, Poland

³ 1st Department of Radiology, Medical University, Lublin, Poland

⁴ Chair and Department of Rheumatology and Connective Tissue Diseases, Medical University, Lublin, Poland

A – Research concept and design, B – Collection and/or assembly of data, C – Data analysis and interpretation, D – Writing the article, E – Critical revision of the article, F – Final approval of the article

Grzywa-Celińska A, Emeryk-Maksymiuk J, Tarkowski P, Krusiński A, Redestowicz K, Siwiec J, Suszek D. Giant haematoma of the posterior compartment of thigh in a patient with coronavirus disease 19 pneumonia and pulmonary embolism – Case Report. *Ann Agric Environ Med*. doi: 10.26444/aaem/157419

Abstract

Introduction. During the Coronavirus-19 (Covid-19) pandemic, a significant increase in the frequency of complications in the form of venous thrombosis was observed. However, there is also the other side of the coin – an increase in the tendency to bleeding in the course of COVID19.

Case Report. We present the case of a patient hospitalised in the COVID-19 Isolation Ward due to severe pneumonia in the course of SARS-CoV2 infection. She developed respiratory failure requiring a non-invasive mechanical ventilation. In addition, pulmonary embolism was diagnosed, the treatment with low molecule heparin was initiated. Soon, the patient developed a huge haematoma of the posterior compartment of the thigh causing deformation and dysfunction of the limb and resulting with acute haemorrhagic anaemia.

Conclusion. Our article is a contribution to the discussion on the need to pay attention to the possibility of haemorrhagic complications in the course of anticoagulant treatment due to venous thrombosis in COVID-19 patients.

Key words

haematoma, covid19, anticoagulant

INTRODUCTION

Since the outbreak of the Coronavirus-19 (COVID-19) pandemic, the world has been facing numerous, sometimes surprising, complications of this dangerous disease. Interestingly, COVID-19 is associated with a significant risk of venous thrombosis, while, on the other hand, the risk of bleeding also increases.

The case is presented of a patient hospitalised in the Isolation Unit of the Department of Pulmonology of the Medical University in Lublin, Poland, due to SARS-CoV2 infection, who developed a huge haematoma of the posterior compartment of the thigh causing significant deformation and dysfunction of the limb.

CASE REPORT

A 63-year-old female patient was admitted to the Isolation Unit due to respiratory tract infection and a positive RT-PCR test for SARS-CoV2 infection. A chest angio-CT scan

revealed the typical changes of coronavirus-19 pneumonia, and confirmed the presence of a peripheral pulmonary embolism. Due to hypoxaemic respiratory failure stated in arterial blood gases, passive oxygen therapy was initiated, followed by high flow nasal oxygen therapy, and finally, non-invasive ventilation. The patient was treated according to the current guidelines for COVID-19 [1]. Treatment with a therapeutic dose of low molecule heparin was also administered. A significant clinical improvement was soon observed. The day before the planned discharge from hospital, her general condition suddenly deteriorated: the skin was pale, tachycardia up to 125/min, but the respiratory state remained stable. The patient reported that she had hit the bed rail the day before. Physical examination showed a giant haematoma in the left gluteal region descending towards the thigh and left popliteal fossa. Ultrasound revealed a large inter- and intramuscular haematoma of the posterior compartment of the thigh and in the gluteal region, with an irregular blood reservoir of 12.8 × 5.5 × 3.8 cm within the posterior compartment. Extensive subcutaneous haematoma of the gluteal region, thigh, popliteal fossa and upper calf was described (Fig. 1, 2, 3). In order to confirm active bleeding, an angio-CT of the pelvis and limbs was performed which confirmed an extensive haematoma and hyperdense bands of extravasated contrast within that area – sites of active

✉ Corresponding author: Anna Grzywa-Celińska, Chair and Department of Pneumology, Oncology and Allergology, Medical University, Lublin, Poland email: annagrzywacelinska@umlub.pl

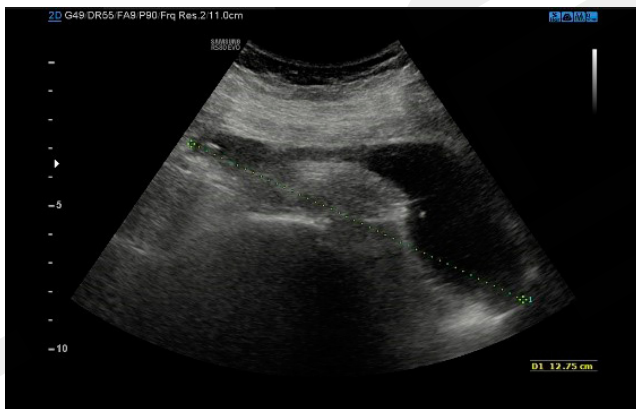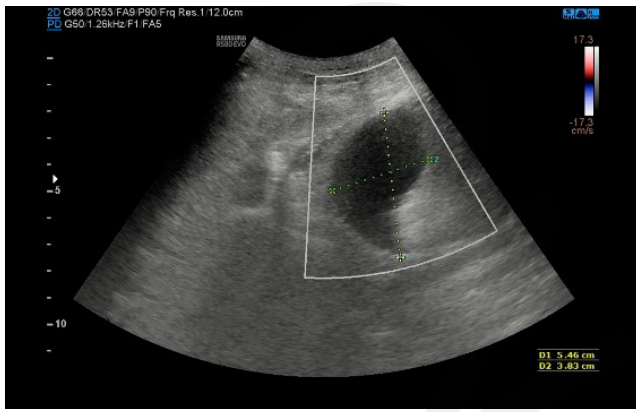


Figure 1,2. Ultrasound image of posterior compartment of thigh in axial (A) and sagittal (B) plane. Massive irregular free fluid – blood collection between muscles within the posterior compartment

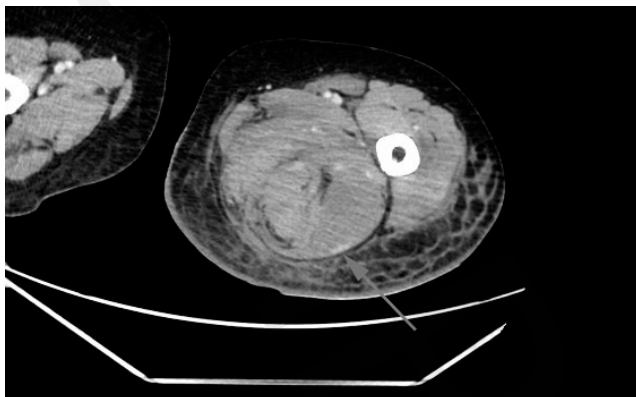
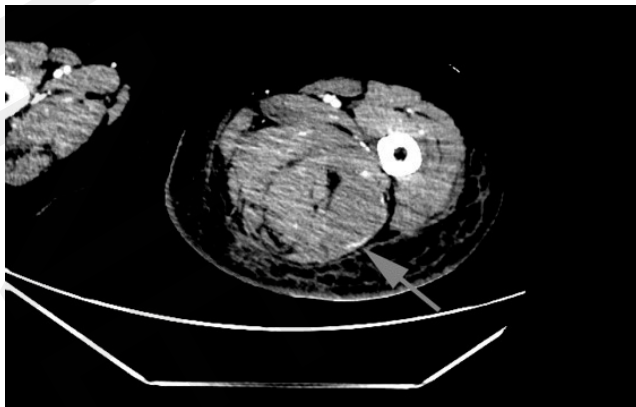


Figure 3,4. Venous phase of angio-CT showing active site of arterial bleeding (arrow) and collection of fluid in posterior compartment and extensive oedema and haematoma of subcutaneous tissue

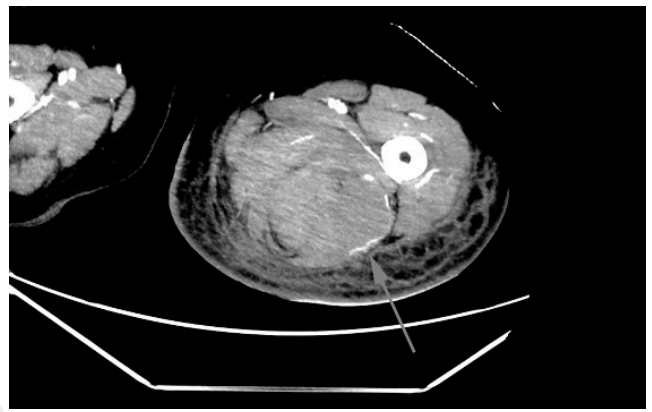


Figure 5. Maximum intensity projection MPR of angio-CT delayed phase showing extravasated contrast within the haematoma – active bleeding (arrow)

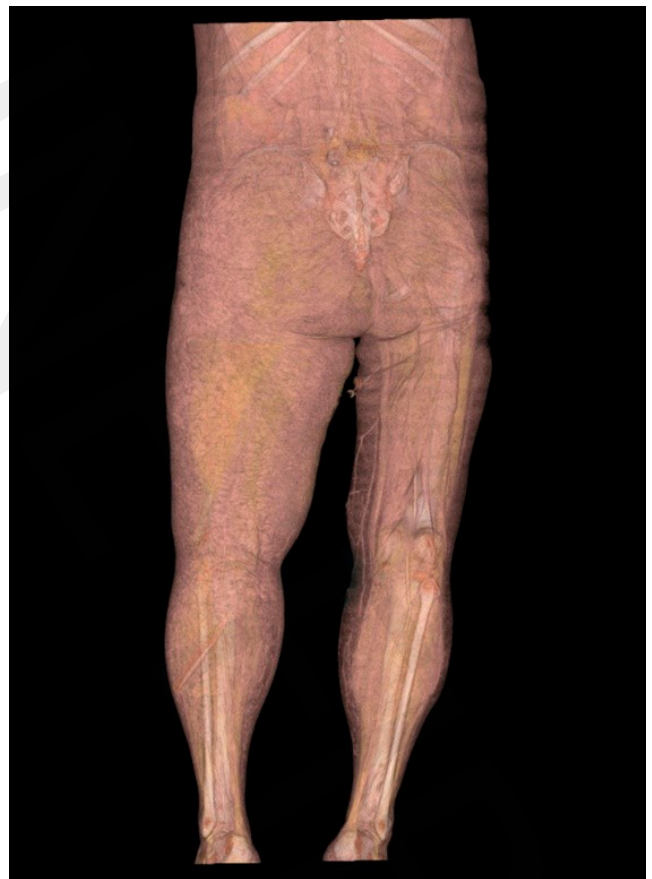

Figure 6. Volume render image of both lower limbs, showing enlargement of left thigh

bleeding (Fig. 4, 5, 6). Due to the sudden and dramatic deterioration of the patient, decrease in haemoglobin concentration from 12.7 to 5.9 g/dl and platelet rate decrease from 194 to 64 × 103/μl, embolization of the vessels of the left lower limb was attempted, but no site of bleeding was found at time of procedure. Other coagulation parameters at that time were as follows: D-dimers – 120 ng/ml (normal value <500), prothrombin time – 14s (normal value 9.4 -12.5) and fibrinogen – 1.9g/l (normal value 2.0 -3.9). According to the International Society for Thrombosis and Haemostasis (ISTH) scoring system for the disseminated intravascular coagulation (DIC) [2], the results were not suggestive for overt DIC.

Despite the transfusion of a total of eight units of red cells concentrate, four units of fresh frozen plasma and 2 units of platelet concentrate, the haemoglobin level did not stabilise and a constant progression of the haematoma volume was observed in the left lower limb. Due to active bleeding, low molecule heparin was withdrawn despite pulmonary embolism. After obtaining a negative antigen test result for SARS-CoV2 infection, the patient, in a moderately severe condition, was transferred to the Department of Vascular Surgery where gradual absorption of the haematoma and improvement of blood count parameters were observed in a one-week follow-up.

After stabilisation of the clinical condition and the slight regression of the haematoma, enoxaparin was restarted, but at a reduced dose. The patient was discharged home in a stable condition, but required home oxygen therapy. To-date, she has remained under the observation of the Lung Disease Out-patient Department. A recently performed examination of arterial blood gases no longer showed the features of respiratory failure and home oxygen treatment was withdrawn. Computed tomography examination of the lungs showed a significant regression of changes typical of pneumonia in the course of SARS-CoV2 infection. Currently, the patient does not require treatment with any pulmonary drugs. Anti-coagulant treatment has been completed. The limb looks normal, with only a small discolouration of the skin in the popliteal area.

DISCUSSION

Patients with SARS-CoV2 infection are at a remarkably higher risk of thrombotic complications [3, 4, 5], as observed in the presented case. The incidence of thrombotic complications accounts for over 30% of cases in Intensive Care Units [4]. The odds for occurrence of symptomatic venous thrombosis in hospitalised patients with SARS-CoV2 infection were 5.94 for severe and 2.79 times higher for non-severe, higher compared to patients without infection [6]. Numerous prediction factors for the occurrence of venous thrombosis in the course of COVID-19 have been hypothesised including: dysregulation of blood pressure, electrolyte imbalance, renal dysfunction, liver failure, and elevated inflammatory markers [3].

However, patients with COVID-19 often experience bleeding of different etiologies and locations [7, 8, 9, 10, 11, 12]. The major risk factors of bleeding in patients with COVID-19 are thrombocytopenia, DIC, anti-coagulant administration, LDH elevation, increased inflammatory response and prolonged tissue hypoxia [13, 14, 15]. The possibility of extending the half-life of heparin in patients with renal complications in the course of COVID-19 should also be taken into consideration [16]. It cannot be excluded that endothelium micro-damages caused by COVID-19, in addition to promoting thrombophilia, may also lead to a tendency to bleeding, which will be intensified under the influence of anti-coagulant treatment. Heparins do not have to be the only cause of bleeding – dexametasone commonly used in COVID-19 may be responsible for inhibiting thrombocyte aggregation [17].

The intramuscular haemorrhage in the presented case met the ISTH (International Society for Thrombosis and Haemostasis) criteria for major bleedings [18]. The risk of major bleeding in patients with COVID-19 accounts for

3.9% overall, while in patients treated with anti-coagulants – from 21%-14% [14, 15, 19]. The risk of clinically significant bleeding in COVID-19 patients treated with anti-coagulants for venous thrombosis was found to be twice as high as in patients taking anti-coagulants due to atrial fibrillation [15].

The literature describes cases of patients with COVID-19 who experienced spontaneous bleeding during low molecule heparin treatment, even without thrombocytopenia or chronic DIC markers [11, 20]. The presented patient had no signs of DIC, and moderate thrombocytopenia appeared secondary to bleeding. Most likely, the occurrence of such a huge haematoma had a multifactorial aetiology, but the trauma of the thigh area should be considered the main causative factor. Regardless of the cause, major haemorrhages place the patients in a high risk of immediate morbidity [11].

It should be emphasised, however, that the size of the haematoma was disproportionate to the injury in the presented patient, although in the case of COVID-19, even completely spontaneous spontaneous muscle haematoma (SMH), i.e. muscle bleeding, has been described. A retrospective analysis by Abate et al. found that SMH occurred in 2.1% of Covid-19 patients receiving a prophylactic or therapeutic dose of enoxaparin, and the risk of death among them was 32.4%. Data for patients without Covid-19 estimate the risk of SMH at 0.6%, and the risk of death at 4.5% [17].

An important role in the diagnostics of bleeding is played by the angio-CT scanning as it often allows location of the bleeding site. In the treatment of bleeding, apart from transfusion of blood components, vascular embolization and surgical treatment are important. The effectiveness of embolization is estimated at 90% and allows returning to anti-coagulant treatment in patients who require it [16, 17]. In the presented patient, an afore-mentioned angio-CT was performed which revealed the bleeding site. However, the arteriography no longer showed active bleeding, consequently, embolization was abandoned. No indications for surgery were determined and conservative treatment implemented, which eventually proved to be effective. However, limiting treatment only to the transfusion of blood components forced the withholding of anti-coagulation treatment in this patient with pneumonia and pulmonary emboli in the course of COVID-19, which increased the risk of further thromboembolic complications.

CONCLUSION

Taking into account the described case and other cases cited, it can be assumed that vascular disorders in the course of COVID-19 may be not only of hypercoagulability, but also increased bleeding risk, particularly in patients treated with anti-coagulants. For this reason it is very important to pay attention to the symptoms presented or reported by patients, which could suggest the occurrence of severe complications, as described in this case report.

REFERENCES

1. Recommendations for the diagnosis and therapy of SARS-CoV-2 infections of the Polish Society of Epidemiologists and Infectiologists of November 12, 2021. Annex 1 to the recommendation of April 26, 2021. <https://www.mp.pl/covid19/zale...,zalecenia-diagnostyki-i->

- terapii-zakazen-sars-cov-2-polskiego-towarzystwa-epidemiologow-i-lekarzy-chorob-zakaznych-z-dnia-12-listopada-2021-roku.
- Levi M, Toh CH, Thachil J, et al. Guidelines for the diagnosis and management of disseminated intravascular coagulation. *British Committee for Standards in Haematology. Br J Haematol.* 2009;145(1):24–33. <https://doi:10.1111/j.1365-2141.2009.07600.x>
 - Lee Y, Jehangir Q, Li P, et al. Venous thromboembolism in COVID-19 patients and prediction model: a multicenter cohort study. *BMC Infect Dis.* 2022;22(1):462. <https://doi:10.1186/s12879-022...>
 - Llitjos JF, Leclerc M, Chochois C, et al. High incidence of venous thromboembolic events in anticoagulated severe COVID-19 patients. *J Thromb Haemost.* 2020;18(7):1743–1746. <https://doi:10.1111/jth.14869>
 - Klok FA, Kruip MJHA, van der Meer NJM, et al. Incidence of thrombotic complications in critically ill ICU patients with COVID-19. *Thromb Res.* 2020;191:145–147. <https://doi:10.1016/j.thromres.2020.04.013>
 - Li JY, Wang HF, Yin P, et al. Clinical characteristics and risk factors for symptomatic venous thromboembolism in hospitalized COVID-19 patients: a multicenter retrospective study. *J Thromb Haemost.* 2021;19(4):1.
 - Mahmoudabadi HZ, Hadadi A, Fattahi MR, et al. Rectus Sheath Haematoma in COVID-19 Patients as a Mortal Complication: A Retrospective Report. *Int J Clin Pract.* 2022;2022:7436827. <https://doi:10.1155/2022/7436827>
 - Nakamura H, Ouchi G, Miyagi K, et al. Case Report: Iliopsoas Haematoma during the Clinical Course of Severe COVID-19 in Two Male Patients. *Am J Tropical Med Hyg.* 2021;104(3):1018–1021. <https://doi:10.4269/ajtmh.20-1...>
 - Sabouri M, Rezvani M, Aminmansour B, et al. Spontaneous intramedullary haematoma in a patient with COVID-19 infection: A case report. *Clin Case Rep.* 2022;10(2):e05387. <https://doi:10.1002/ccr3.5387>
 - Rogani S, Calsolaro V, Franchi R, et al. Spontaneous muscle haematoma in older patients with COVID-19: two case reports and literature review. *BMC Geriatr.* 2020;20(1):539. <https://doi:10.1186/s12877-020-01963-4>
 - Singh B, Mechineni A, Kaur P, et al. COVID-19 and bleeding at unusual locations: Report of four cases. *Hematol Transfus Cell Ther.* 2021;43(2):214–218.
 - Patel I, Akoluk A, Douedi S, et al. Life-Threatening Psoas Haematoma due to Retroperitoneal Hemorrhage in a COVID-19 Patient on Enoxaparin Treated With Arterial Embolization: A Case Report. *J Clin Med Res.* 2020;12(7):458–461. <https://doi:10.14740/jocmr4256>
 - Dorgalaleh A. Bleeding and Bleeding Risk in COVID-19. *Semin Thromb Hemost.* 2020;46(7):815–818
 - Jiménez D, García-Sánchez A, Rali P, et al. Incidence of VTE and Bleeding Among Hospitalized Patients with Coronavirus Disease 2019: A Systematic Review and Meta-analysis. *Chest.* 2021;159(3):1182–1196.
 - Prince MR, Dev H, Lane EG, et al. Major hemorrhage and mortality in COVID-19 patients on therapeutic anticoagulation for venous thromboembolism. *J Thromb Thrombolysis.* 2022:1–7. <https://doi:10.1007/s11239-022...>
 - López-Martínez L, Molina-Nuevo JD, Pedrosa-Jiménez MJ, et al. Spontaneous Haematomas in Anticoagulated Covid-19 Patients: Diagnosis and Treatment by Embolization. *Cardiovasc Intervent Radiol.* 2022;45(7):1001–1006. <https://doi:10.1007/s00270-021...>
 - Abate V, Casoria A, Rendina D, et al. Spontaneous Muscle Haematoma in Patients with COVID-19: A Systematic Literature Review with Description of an Additional Case Series. *Semin Thromb Hemost.* 2022;48(1):100–108. <https://doi:10.1055/s-0041-1732370>
 - Schulman S, Kearon C. Subcommittee on Control of Anticoagulation of the Scientific and Standardization Committee of the International Society on Thrombosis and Haemostasis. Definition of major bleeding in clinical investigations of antihemostatic medicinal products in non-surgical patients. *J Thromb Haemost.* 2005;3(4):692–4. <https://doi:10.1111/j.1538-7836.2005.01204.x>
 - Godier A, Clause D, Meslin S, et al. Major bleeding complications in critically ill patients with COVID-19 pneumonia. *J Thromb Thrombolysis.* 2021;52(1):18–21. <https://doi:10.1007/s11239-021-02403-9>
 - Boira I, Esteban V, Vañes S, et al. Major Bleeding Complications in COVID-19 Patients. *Cureus.* 2021;13(8):e16816.