



# *Cryptosporidium* spp. and *Blastocystis* spp. coinfection as a reason of an acute diarrhea in a young healthy veterinary Polish student – Case report

Łukasz Augustyn Pielok<sup>1,A,D</sup>, Joanna Swarczewicz<sup>2,B</sup>, Krystyna Frąckowiak<sup>3,C</sup>,  
Monika Lisiecka<sup>4,B</sup>

<sup>1</sup> Department of Tropical and Parasitic Diseases Medical University, Poznań, Poland

<sup>2</sup> Central Microbiology Laboratory, H. Świącicki University Hospital, Poznań, Poland

<sup>3</sup> Parasitology Laboratory, H.Świącicki University Hospital, Poznań, Poland

<sup>4</sup> Central Microbiology Laboratory, J. Struś City Hospital, Poznań, Poland

A – Research concept and design, B – Collection and/or assembly of data, C – Data analysis and interpretation, D – Writing the article, E – Critical revision of the article, F – Final approval of the article

Łukasz Augustyn Pielok<sup>1,A,D</sup>, Joanna Swarczewicz<sup>2,B</sup>, Krystyna Frąckowiak<sup>3,C</sup>, Monika Lisiecka. *Cryptosporidium* spp. and *Blastocystis* spp. coinfection as a reason of an acute diarrhea in a young healthy veterinary Polish student- a case report. Ann Agric Environ Med. doi: 10.26444/aaem/152206

## Abstract

**Objectives.** *Cryptosporidium* belongs to enteric parasites responsible for prolonged symptoms in the gastrointestinal tract, both in immunocompetent and immunocompromised individuals. One of the risk factors of infection is contact with an infected person or animals (cattle). The case is described of a young man admitted to the Department of Tropical and Parasitic Diseases of the Medical University in Poznań, Poland, because of watery diarrhea with high fever and in whom symptomatic treatment did not produce any improvement.

**Materials and method.** A 21-year-old male was examined and his epidemiologic history obtained. Primary blood test, anti-Toxocara IgG (ELISA) and anti-Toxoplasma gondii IgG and IgM (ELISA) were performed. PCR detected 16 enteropathogens in a stool sample. Microscopic parasitic stool examination was also performed based on Ziehl-Neelsen method, which allowed the assessment of the presence of cryptosporidium life stages.

**Results.** Epidemiology data provided information that the patient was a veterinary student who therefore had many contacts with domestic animals. Multiplex PCR detected a genetic material of *Cryptosporidium*. The result was confirmed with repeated positive direct stool examinations which gave the evidence of *Cryptosporidium* spp. oocysts and vacuolar forms of *Blastocystis* spp.

**Conclusions.** 1) *Cryptosporidium* is responsible for watery diarrhea in healthy individuals. 2) Contact with animals (cattle) is a potential risk factor for infection. 3) Protozoan co-infection should be treated to shorten the symptomatic period and to avoid post-infection complications. 4) Different diagnostic methods increase the possibility to establish appropriate diagnosis

## Key words

*Cryptosporidium* spp., *Blastocystis* spp., diarrhea, zoonotic disease, co-infection

## INTRODUCTION

*Cryptosporidium* is a protozoan parasite of medical and veterinary importance that causes gastroenteritis in a variety of vertebrate hosts, including human beings. Rzeżutka et al. indicated that these parasites have been recognized in more than 150 animal species [1]. *Cryptosporidium* has emerged as a significant cause of a diarrhoeal disease worldwide, the infection is characterized by watery diarrhea, abdominal pain, nausea and low-grade fever. It represents a major public health problem in both developed and developing countries, and usually occurs in immunocompromised individuals for whom it can be life-threatening [2]. This infection can also be diagnosed in healthy subjects with normal function of the immune system [3]. The risk factors of infection include: ingestion of contaminated food or water, swimming

or bathing in contaminated water, direct contact with an infected person or an animal actively shedding oocysts, and finally, travel to endemic areas [4].

*Cryptosporidium* spp. oocysts are highly infective, studies conducted with the participation of human volunteers have shown that as few as 10 oocysts can cause an infection in a healthy adult. There is no single gold-standard diagnostic test for acute cryptosporidiosis: reliable diagnostic tests have yet to be developed. Without appropriate microbiological testing of stool samples, it is impossible to establish an accurate diagnosis in a symptomatic patient [5]. Several methods are available for detection of *Cryptosporidium* spp. and in clinical pathology laboratories diagnosis is still based mainly on microscopic detection via stains. Acid fast modified Ziehl-Neelsen staining is one of the most common of the different techniques.

Nucleic acid-based methods, such as Multiplex PCR assays, have also been used for the detection of cryptosporidiosis, methods which have the advantages of identifying mixed infections [6]. All diagnostic methods have different

✉ Address for correspondence: Łukasz Augustyn Pielok, Tropical and Parasitic Diseases Department, Medical University, Poznań, Poland  
E-mail: l.augustyn@wp.pl

Received: 05.06.2022; accepted: 19.07.2022; first published: 01.08.2022

capabilities and limitations [7], therefore, the best way is to use combined techniques.

There is still no specific therapeutic or preventive modality approved for cryptosporidiosis, although several drugs are used to eradicate the parasite [8].

## OBJECTIVE

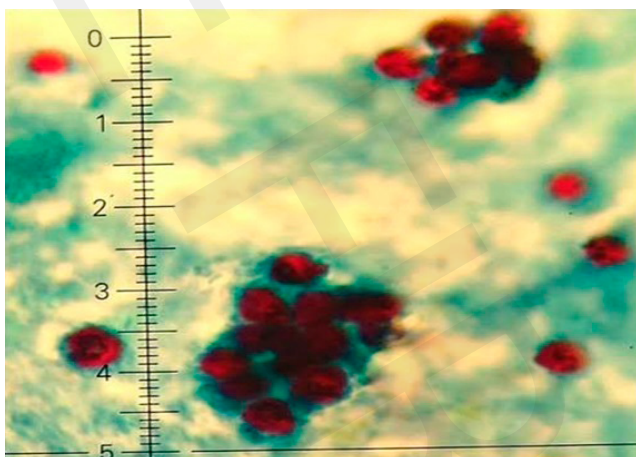
This case report describes a male patient presenting watery diarrhea admitted to the Department of Tropical and Parasitic Diseases of the Medical University in Poznań, Poland, to investigate the possibility of the presence of parasitic infections in the alimentary tract.

## CASE REPORT

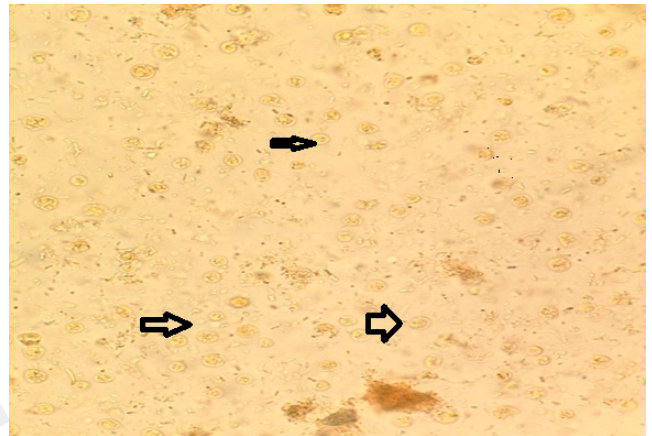
A 21-year-old 2<sup>nd</sup>-year male veterinary student was admitted to the Department of Tropical and Parasitic Diseases of Poznań Medical University because of multiple watery, loose stools, abdominal pains and fever. All these symptoms developed 2 days before admission to hospital. On admission, physical examination revealed abdominal tenderness, enhanced bowel movements and low-grade fever. Symptomatic treatment with *Tanninum albuminatum* (Taninal 3x1000mg) and *Lactobacillus plantarum* (Sanprobi IBS 1x1) did not produce any improvement.

Primary laboratory tests showed slight leukopenia (WBC 2.62 G/l) and an elevated level of CRP (50mg/l, normal range <5.0mg/l). Multiplex PCR test (FilmArray, Gastrointestinal (GI) Panel, bioMerieux) of the stool sample detected genetic material of *Cryptosporidium*. Repeated microscopic stool examinations (Ziehl-Neelsen staining) showed evidence of *Cryptosporidium* spp. oocysts (Fig. 1) as well as vacuolar forms of *Blastocystis* spp. (Fig. 2). ELISA 4-th generation HIV test was negative, anti-HCV – negative, HBSAg – negative, anti-Toxocara IgG (ELISA) – negative, anti-Toxoplasma gondi IgG and IgM (ECLIA) did not reveal the presence of monoclonal specific antibodies.

The patient was treated with norfloxacin (2x400 mg), and because nitazoxanid was unavailable, with paromomycin (Humatin, 3x500mg) and a single dose of tynidazole (Tynidazol 1x3.0g). After completing the treatment, all



**Figure 1.** Numerous *Cryptosporidium* spp. oocyst detected in the stool sample of the patient (Acid-fast modified Ziehl-Neelsen staining)



**Figure 2.** Vacuolar forms of *Blastocystis* spp. (black arrows) detected in the patient's stool – microscopic parasitic stool examination (smear in 0.9% NaCl)

symptoms resolved and the patient was discharged from hospital.

Outpatient follow-up performed after 2 weeks confirmed eradication of the parasites.

## DISCUSSION

*Cryptosporidium* spp. has emerged as a significant cause of diarrhoeal disease worldwide: an infection caused by the parasite is characterized by watery diarrhea, abdominal pain, nausea and low-grade fever.

*Cryptosporidium parvum* can cause an infection in over 155 mammalian hosts, including humans. In Europe, its prevalence increased from 0.1 to 14% – based on oocysts detection in faecal specimens [9].

*Cryptosporidium*, an intracellular parasite, is one of the most commonly reported enteric parasites in both immunocompetent and immunocompromised individuals worldwide. Unfortunately, in most countries it is underdiagnosed and underreported because there is no single gold-standard diagnostic test for acute cryptosporidiosis, accessible and accurate diagnostic tests have not yet been developed [10].

Humans are predominantly infected with the zoonotic species *Cryptosporidium parvum* or the anthroponotic species *Cryptosporidium hominis* [11]. Contact with infected domestic animals can pose a significant risk factor. In the literature there are a number of case reports describing veterinary students who became infected during practical training on cattle farms [12]. Calves can be a major reservoir as *C. parvum*-contaminated calf manure shows high oocyst concentrations [13]. The immunity of the host, both innate and adaptive, has a major impact on the severity of the disease and its prognosis. In healthy individuals, an infection with the parasite results in diarrhea and transient gastroenteritis lasting up to 2 weeks, with symptoms resolving without treatment [6]. However, *Cryptosporidium* can sometimes cause persistent symptoms in immunocompetent subjects that extend beyond the acute illness. Some of these signs or symptoms may be indicative of post-infectious irritable bowel syndrome [14].

Treatment of cryptosporidiosis is difficult and the therapeutic options are still limited. Clinical trials have examined the efficacy of macrolides, paromomycine and

nitazoxanid (in HIV-positive patients). All have partial efficacy in reducing symptoms in immunocompetent subjects [15,16]. Treatment might be taken into consideration even in asymptomatic individuals in order to avoid further contamination of the surroundings, as the illness can be spread from person-to-person by direct contact.

In the case described above, the diagnosis of the *Cryptosporidium* infection was established on the basis of the patient's epidemiological history – the patient reported of direct contact with animals (cattle) on several farms during practical training, and denied contact with animals at home. Two separate laboratory tests – molecular PCR Multitest – whose positive result was confirmed with direct microscopic examination of faecal samples, showed the presence of oocysts in the stool. Modified Ziehl-Neelsen staining with 94% sensitivity and 100% specificity seems to be useful and has enough accuracy for *Cryptosporidium* diagnosis, even for low risk patients. This direct diagnostic method is simple and cheap but requires to be used by an expert microscopic diagnostician [17].

The decision to start antibiotic treatment was taken because symptoms persisted despite symptomatic treatment, because the patient was infected with two separate protozoan parasites (*Cryptosporidium* spp. and *Blastocystis* spp.), and also to avoid contamination of the patient's surroundings. The role of *Blastocystis* spp. in human pathology has widely discussed and is now even regarded as a parasitic pathogen [18–20]; therefore, it is worthwhile highlighting this in the diagnosis. Combination treatment might decrease the risk of post-infectious irritable bowel syndrome.

The authors suggest that molecular assays should be performed in combination with microscopic examination of aecal samples as this increases the chance of establishing an accurate diagnosis.

## CONCLUSIONS

1. *Cryptosporidium* spp. infection should be taken into consideration as a potential agent responsible for diarrhea in immunocompetent individuals
2. Contact with cattle is a risk factor for cryptosporidiosis in humans.
3. Co-infection with *Cryptosporidium* spp. and *Blastocystis* spp. requires combination treatment.
4. PCR assays used together with direct microscopy of stool samples is the best method for detecting protozoan parasites.

## REFERENCES

1. Rzeżutka A, Kaupke A, Gorzkowski B. Detection of *Cryptosporidium parvum* in a Red-Eared Slider-Turtle (*Trachemys scripta elegans*), a Noted Invasive Alien Species, catured in a Rural Aquatic Ecosystem in Eastern Poland. *Acta Parasitol.* 2020 Sep;65(3):768–773. doi:10.2478/s11686-020-00180-8. Epub 2020 Mar 5
2. Cassio SM, Pozio E. Advances in the epidemiology, diagnosis and treatment of cryptosporidiosis. *Expert Rev Anti Infect Ther.* 2006 Jun;4(3):429–43. doi:10.1586/14787210.4.3.4293
3. Pielok Ł, Nowak SzP, Kłudkowska M, Frąckowiak K, Kuszel Ł, Zmora P, Stefaniak J. Massive *Cryptosporidium* infection and chronic diarrhea in HIV-negative patients. *Parasitol Res.* 2019 Jun;118(6):1937–1942. doi:10.1007/s00436-019-0632-0
4. Bouzid M, Hunter PR, Chalmers RM, Tyler KM. *Cryptosporidium* pathogenicity and virulence. *Clin Microbiol Rev.* 2013 Jan;26(1):115–34. doi:10.1128/CMR.00076-12
5. Tallant C, Huddleston P, Alshabesi A, Misra S. Acute, Cerebral *Cryptosporidiosis* in an Immunocompetent Pediatric Patient. *Clin Pract.* 2016 Jul 4;6(2):837. doi:10.4081/cp.2016.837.eCollection 2016 Apr.26
6. Ryan U, Zahedi A, Papanini A. *Cryptosporidiosis* in humans and animals – a one health approach to prophylaxis. *Parasite Immunol.* 2016 Sep;38(9):535–47. doi:10.1111/pim.12350
7. Tzipori S, Ward H. *Cryptosporidiosis*: biology, pathogenesis and disease. *Microbes Infect.* 2002 Aug;4(10):1047–58. doi:10.1016/s1286-4579(2)01629-5
8. Hossa EM, Omeci B, DeRosa MC, Dixon BR, Sattar SA, Iqbal A. A review of *Cryptosporidium* spp. and their detection in water. *Water Sci Technol.* 2021 Jan;83(1):1–25. doi:10.2166/wst.2020.515
9. Fayer R. *Cryptosporidium*: a water-borne zoonotic parasite. *Vet Parasitol.* 2004 Dec 9;126(1–2):37–56. doi:10.1016/i.vetpar.2004.09.004
10. Chalmers RM, Alexander C. Defining the diagnosis of cryptosporidiosis. *Lancet Infect Dis.* 2021 May;21(5):589–590. doi:10.1016/S1473-3099(20)30575-2
11. Kothavade RJ. Challenges in understanding the immunopathogenesis of *Cryptosporidiosis* in human. *J Clin Microbiol Infect Dis.* 2011 Dec;30(12):1461–72.
12. Gaul R, Soutar RH, Hanson M, Fraser C, Chalmers R. Outbreak of *Cryptosporidiosis* among veterinary students. *Vet Rec.* 2008 Jun 28;162(26):843–5. doi:10.1136/vr.162.26.843
13. Kiuross P, Beser J, Troell K, Axen C, Bjornkman C, Lebbad M, Winiecka-Kruszel J, Lindth J, Lofdahl M. *Cryptosporidium parvum* infections in a cohort of veterinary students in Sweden. *Epidemiol Infect.* 2015 Oct;143(13):2748–56. doi:10.1017/S0950268814003318
14. Caccis SM, Chalmers RM. Human cryptosporidiosis in Europe. *Clin Microbiol Infect.* 2016 Jun;22(6):471–80. doi:10.1016/j.cmi.2016.04.021
15. Chako CZ, Tyler JW, Schultz LG, Chiguma L, Beernitsen BT. *Cryptosporidiosis* in People: It's Not Just About the Cows. *J Vet Intern Med.* Jan-Feb 2010;24(1):37–43. doi:10.1111/j.1939-1676.2009.0431.x
16. Pantenburg B, Cabade M, White Jr AC. Treatment of cryptosporidiosis. *Expert Rev Anti Infect Ther.* 2009 May;7(4):385–91. doi:10.1586/eri.24
17. Tahvildar-Biderouni F, Salehi N. detection of *Cryptosporidium* infection by modified Ziehl-Neelsen and PCR methods in children with diarrheal samples in pediatric hospitals in Teheran. *Gastroenterol Hepatol Bed Bench.* 2014 Spring;7(2):125–130.
18. Duda A, Kosik-Bogacka D, Lanocka N, Szymański S. *Blastocystis hominis* parasites or commensals. *Ann Acad Med Stetin.* 2014;60(1):23–8.
19. Taghipour A, Rayatdoost E, Bairami A, Bahadory S, Abdali A. Are *Blastocystis hominis* and *Cryptosporidium* spp. playing a positive role in colorectal cancer risk? A systemic review and meta analysis. *Infect Agent cancer.* 2020 Jun 17;17(1):32. doi:10.1186/s13027-022-00447-x
20. Yellanthoor RB. Acute gastroenteritis due to *Blastocystis hominis* in an adolescent boy. *BMJ Case Rep.* 2020. Dec 21;13(12):e237810. doi:10.1136/bcr-2020-237810