



Correlation of clinical symptoms, endoscopic features and density of oesophageal eosinophilia in children with newly-diagnosed eosinophilic esophagitis

Andrzej Załęski^{1,2,A-F}, Marcin Banasiuk^{3,C-D,F}, Katarzyna Sokół-Łupińska^{4,B,D,F},
Katarzyna Karolewska-Bochenek^{3,A,E-F}, Aleksandra Banaszekiewicz^{3,A,C-F}

¹ Department of Infectious Diseases, Tropical Diseases and Hepatology, Medical University, Warsaw, Poland

² Hospital of Infectious Diseases, Warsaw, Poland

³ Department of Paediatric Gastroenterology and Nutrition, Medical University, Warsaw, Poland

⁴ Józef Polikarp Brudziński Public Paediatric Hospital, Warsaw, Poland

A – Research concept and design, B – Collection and/or assembly of data, C – Data analysis and interpretation, D – Writing the article, E – Critical revision of the article, F – Final approval of article

Załęski A, Banasiuk M, Sokół-Łupińska K, Karolewska-Bochenek K, Banaszekiewicz A. Correlation of clinical symptoms, endoscopic features and density of oesophageal eosinophilia in children with newly-diagnosed eosinophilic esophagitis. *Ann Agric Environ Med*. doi: 10.26444/aaem/127180

Abstract

Introduction and objective. Eosinophilic esophagitis (EoE) is an inflammatory immune-mediated oesophageal disease of growing prevalence. The aim of this study is to characterise the clinical symptoms, endoscopic features and histological findings, as well as their possible correlations, in newly-diagnosed EoE paediatric patients.

Materials and method. Between 2009–2018, the clinical records of patients diagnosed with EoE at the Paediatric Hospital in Warsaw, Poland, were retrospectively reviewed. Inclusion criteria were upper gastrointestinal tract symptoms in association with oesophageal mucosal biopsy specimens containing not less than 15 intraepithelial eosinophils per hpf. The prevalence and the possible correlations between symptoms, endoscopic features and the density of eosinophilic infiltration were analysed; the medical history of the comorbidities were also assessed.

Results. The study included 47 children (median age 9.5 years). The most common clinical symptoms were abdominal pain (53%) and GERD-like symptoms (26%). The most common macroscopic changes were white plaques and exudates in 47% and furrows in 34%. A macroscopically normal oesophagus was observed in 28% of the children. The median number of eosinophils was estimated to be 45 eosinophils/hpf (IQR: 30–60), and no significant differences were found between the density of eosinophil infiltration and clinical symptoms or endoscopic features. Moreover, 70% of the children had a history of an allergy disease, older children (>3 years) tended to have pollen allergy more often than younger children ($p < 0.05$).

Conclusions. The density of oesophageal eosinophilia does not correlate with symptoms or endoscopic findings in children with newly-diagnosed EoE.

Key words

clinical evaluation, endoscopy, eosinophil density, paediatric patients

INTRODUCTION

Eosinophilic esophagitis (EoE) is a local, inflammatory immune-mediated oesophageal disease with persistent or relapsing symptoms. In recent years, increased recognition, along with the chronic nature of EoE, has led to a continuous increase in prevalence. Previous studies have reported a 4-fold increase in disease prevalence in children and identified an incidence of approximately 1:10,000 children per year [1]. A typical patient diagnosed with EoE is an atopic, white male (male-female ratio approximately 3:1) who presents symptoms in childhood or in the third or fourth decade of life [2, 3].

According to the 2017 ‘Guidelines on eosinophilic esophagitis: Evidence-based statements and recommendations for diagnosis and management in children and adults’, as well as the earlier (2011) ‘Eosinophilic esophagitis: Updated

consensus recommendations for children and adults’, EoE is a chronic disease that is clinically characterised by symptoms related to oesophageal dysfunction, and histologically characterised by eosinophil-predominant infiltration. To confirm the diagnosis of EoE, other causes of oesophageal eosinophilia should be excluded [4, 5].

There are no pathognomonic clinical features of EoE in children. The clinical manifestation is not specific and varies with age. The most common symptoms in toddlers and infants are feeding difficulties and a disrupted growth pattern. School-aged children usually present with GERD-like symptoms. Food impaction, chest pain and dysphagia are the predominant manifestations of EoE in adolescents [5, 6].

Although no particular features identified in a physical examination are specific for an EoE diagnosis, it is useful to identify signs of comorbid allergic diseases; it is estimated that in the paediatric population with EoE, between 40–90% of patients have another allergic disease. The majority of EoE patients have sensitisation to food, aeroallergens, or both, and 15–43% have IgE-mediated food allergies [3, 5, 7, 8, 9].

Address for correspondence: Aleksandra Banaszekiewicz, Department of Paediatric Gastroenterology and Nutrition, Medical University, Warsaw, Poland
E-mail: aleksandra.banaszekiewicz@gmail.com

Received: 05.05.2020; accepted: 02.09.2020; first published: 14.09.2020

At present, endoscopy with oesophageal biopsy remains the only appropriate and reliable diagnostic tool for EoE. A number of macroscopic changes have been observed in EoE by means of endoscopy, but none can be considered as pathognomonic. These changes include fixed oesophageal rings (trachealisation), transient rings (felinisation), white exudates, longitudinal furrows, oedema, oesophageal narrowing, mucosal fragility, and a tendency for lacerations (crepe paper oesophagus). In addition to EoE patients with these characteristic changes, a macroscopically-normal oesophagus is also seen in up to 30% of paediatric EoE patients [10, 11].

For an optimal evaluation, multiple biopsy specimens from the distal and proximal oesophagus and samples from the gastric antrum and duodenum should be obtained. The eosinophilic infiltration should be isolated from the oesophagus. The minimum threshold for a diagnosis of EoE is 15 eosinophils per high-power field (hpf) in at least one specimen. Other histopathological changes observed in patients with EoE include eosinophilic micro-abscesses, surface layering of eosinophils, extracellular eosinophil granules, basal cell hyperplasia, lamina propria fibrosis and dilated intercellular spaces [10, 11].

The correlation of clinical symptoms and endoscopic features with the density of oesophageal eosinophilia remains unclear, and data from previous studies are inconsistent [5, 12].

OBJECTIVES

There has been an observed increase in the incidence of newly-diagnosed cases of EoE in the paediatric population in recent years. However, data regarding correlations between clinical manifestations and the results of additional procedures in this population remain limited. The aim of the study was to characterise the clinical symptoms, endoscopic features and histological findings of newly-diagnosed EoE in children, and to determine any correlations between the clinical outcomes and the density of eosinophil infiltration.

MATERIALS AND METHOD

The clinical records of all patients diagnosed with EoE (ICD10: K20) in the Public Paediatric Teaching Hospital in Warsaw, Poland, over a 9-year period (November 2009–July 2018), were retrospectively reviewed. Approval for the study was obtained from the Clinical Research Ethics Committee of the Medical University in Warsaw (Consent No. AkBE/97/15) as a part of the trial ‘Paediatric Eosinophilic Esophagitis: Results of the European Retrospective Pediatric Eosinophilic Esophagitis Registry (RetroPEER)’ [13].

The inclusion criteria were upper gastrointestinal tract symptoms in association with oesophageal mucosal biopsy specimens containing ≥ 15 intraepithelial eosinophils per hpf, (400x enlargement, standard size 0.3 mm²) in at least one biopsy specimen, counted after haematoxylin-eosin staining. For each patient, three biopsies were obtained from the oesophagus (estimated diagnostic sensitivity at the level of 97%) [5]. Exclusion criteria were other causes of oesophageal eosinophilia, such as eosinophilic gastrointestinal diseases, achalasia/oesophageal atresia, Crohn’s disease, connective

tissue diseases, drug hypersensitivity, infection (*Candida*, herpes), hypereosinophilic syndrome and graft-versus-host disease.

Distinctive symptoms, such as failure to thrive and disturbances in the weight growth pattern, abdominal/chest pain, other GERD-like symptoms (e.g., nausea, vomiting), dysphagia, odynophagia and food impaction, were analysed. Endoscopic features taken into account were strictures, furrows, rings, white exudates, clotting, oedema and fragility of the oesophageal mucosa, as well as macroscopically normal oesophageal mucosa.

Additionally assessed were the medical history concerning comorbidities, including celiac disease, gastroesophageal reflux disease, atopic history of asthma, rhinitis, food allergies and eczema, as well as allergic diagnostics (IgE level and eosinophilia in peripheral blood smear). Celiac disease was diagnosed on the basis of examination of duodenal mucosa biopsy (Marsh Scale) in conjunction with serology testing (anti-endomysial or anti-transglutaminase antibodies). Gastroesophageal reflux disease (GERD) was diagnosed using 24-hour pH-monitoring, according to well-defined criteria.

Statistical methods. The distribution of continuous variables was analysed by the Shapiro–Wilk test. The data were expressed as the median and interquartile range (IQR). Quantitative data were analysed using the Mann–Whitney U test or Kruskal–Wallis ANOVA when appropriate. Qualitative data were compared using the χ^2 test or the Fisher exact test. A P value of <0.05 was considered statistically significant.

RESULTS

On the basis of the inclusion and exclusion criteria, 47 children (male: female ratio of 2.1: 1), with median age 9.5 years (IQR: 4.1–14.7) were recruited. Those included into the study were not undergoing any pharmacological treatment at the time of diagnosis. The children were divided into three groups: ≤ 3 years, 3–10 years, and ≥ 10 years old. Characteristics of the cohort are shown in Table 1.

Table 1. Characteristics of the cohort

	≤ 3 y.o.	3–10 y.o.	≥ 10 y.o.	P value
n=47	7 (15%)	17 (36%)	23 (49%)	
male (n=32)	5 (16%)	11 (34%)	16 (50%)	
female (n=15)	2 (13%)	6 (40%)	7 (47%)	
Comorbidities				
GERD (n=9)	2 (29%)	3 (18%)	4 (17%)	0.8
Celiac disease (n=4)	1 (14%)	1 (6%)	2 (9%)	0.6
Allergies (n=33)	5 (71%)	14 (83%)	17 (74%)	0.03

The most common clinical symptom was abdominal pain, declared by 53% of the children (n=25). The other most frequent symptoms were GERD-like symptoms (26%; n=12), failure to thrive (23%; n=11) and dysphagia (19%; n=9). Symptom duration ranged between one and 48 months; the ranges were as follow: abdominal pain 1–48 months, GERD-like symptoms 3–44 months, failure to thrive 1–30 months, dysphagia 1–12 months. Symptom analysis in the subgroups ≤ 3 years and ≥ 10 years demonstrated different

patterns of clinical presentation between infants, toddlers and older children and adolescents. The most common clinical symptoms in young children (≤ 3 years) included GERD-like symptoms (43%) and failure to thrive (29%). In comparison, adolescents primarily experienced abdominal pain (61%) and dysphagia (26%), but the differences were not statistically significant ($p > 0.05$).

The endoscopic features visualised included strictures, furrows, rings, white exudates, clotting, oedema and fragility of the oesophageal mucosa. A macroscopically normal oesophagus was observed in 28% of the children ($n=13$). The most common macroscopic changes were white plaques and exudates in 47% ($n=21$) and furrows in 34% ($n=16$). Other typical findings were rings (21%), oedema and fragility of the mucosa (19%), and clotting (9%). Oesophageal stricture was observed in only one patient (4%). None of the patients who presented with dysphagia had a macroscopically normal oesophagus ($p < 0.05$).

The median number of eosinophils in the hpf observation was estimated to be 45 (IQR: 30–60). The vast majority of children (82%; $n=37$) had ≥ 30 eosinophils/hpf on the histological assessment, and among them, 35% had ≥ 60 eosinophils/hpf. The density of eosinophilic infiltration did not correlate with any clinical symptom or endoscopy feature ($p > 0.05$) in the analysed subgroups. The clinical, endoscopic and histopathologic features of the study groups are shown in Table 2. As well in the whole cohort any type of the clinical symptoms was strictly correlated with the density of eosinophilic infiltration ($p > 0.05$), but in the case of dysphagia it was close to statistical significance ($p = 0.06$) (Fig. 1).

Table 2. Clinical, endoscopic and histopathologic features of the study groups

	≤ 3 y.o.	3–10 y.o.	≥ 10 y.o.	P-value
Clinical symptoms				
Dysphagia	1 (14%)	2 (12%)	6 (26%)	0.3
Abdominal pain	1 (14%)	10 (59%)	14 (61%)	0.07
GERD-like symptoms	3 (43%)	5 (29%)	4 (17%)	0.2
Failure to thrive	2 (29%)	5 (29%)	4 (17%)	0.8
Endoscopic features				
Rings	-	3 (18%)	7 (30%)	0.1
White exudates	3 (43%)	9 (53%)	9 (40%)	0.7
Furrows	3 (43%)	5 (29%)	8 (35%)	0.8
Oedema	-	2 (12%)	2 (9%)	0.4
Strictures	-	-	1 (4%)	0.5
Fragility	1 (14%)	2 (12%)	2 (9%)	0.9
Clotting	-	-	4 (17%)	0.2
Normal	4	4	5	0.8
Histopathology result				
Peak eosinophil count/hpf (IQR)	27.5 (IQR: 20–60)	40 (IQR: 40–60)	40 (IQR: 35–60)	0.4

IQR – interquartile range

Data in the subgroup of patients with a macroscopically normal oesophagus were also analysed ($n=13$) (Tab. 3). In these children, the most common clinical presentation was also abdominal pain (46%) and GERD-like symptoms (31%). The median number of eosinophils per hpf was estimated to

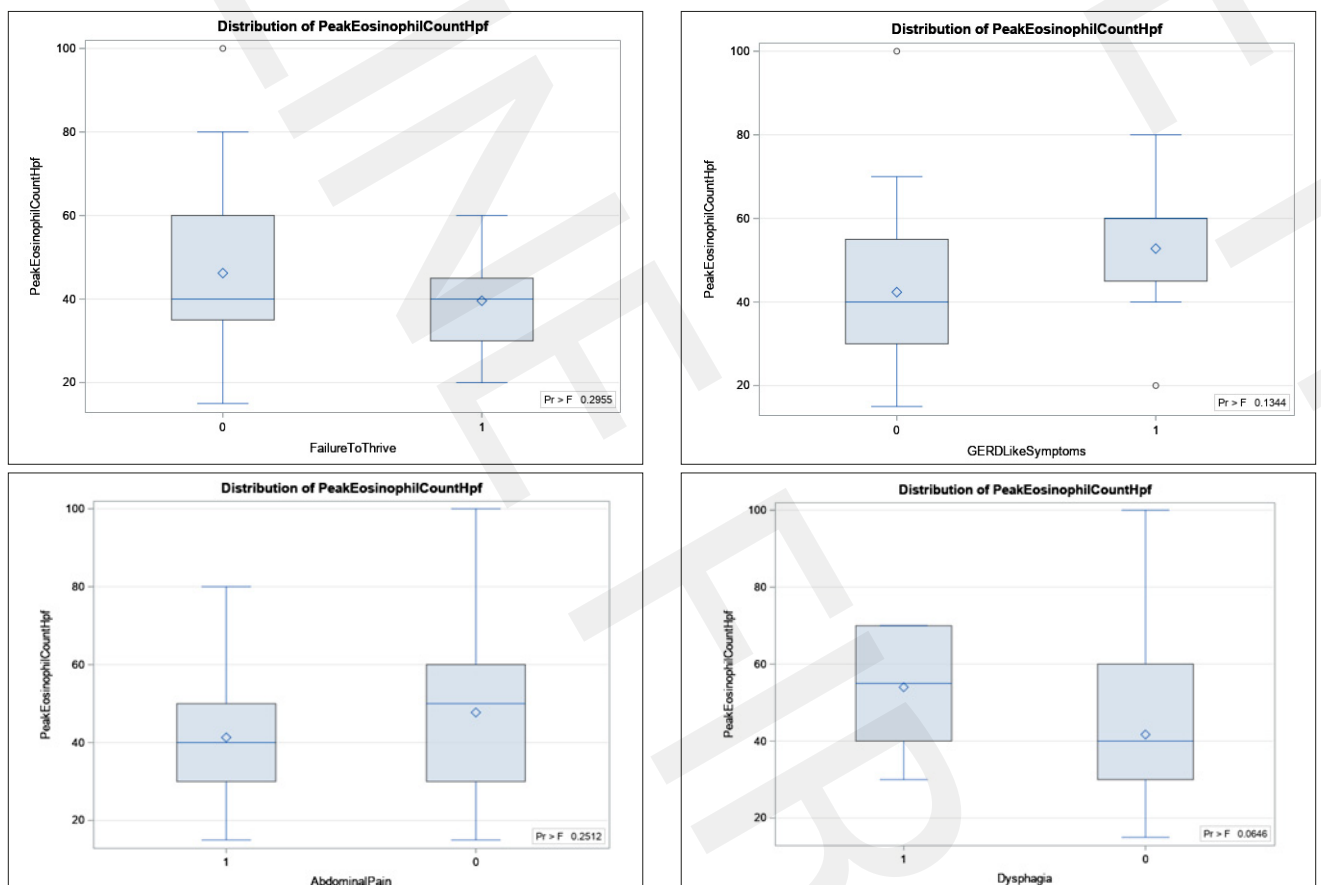


Figure 1. Distribution of peak eosinophil count per high power field according to the symptoms in whole cohort (1 – presence of the symptom, 0 – without the symptom)

be 40 (IQR: 25–60), and did not significantly differ from the whole cohort ($p>0.05$).

Table 3. Characteristics of patients with macroscopically normal oesophagus

	≤3 y.o.	3–10 y.o.	≥10 y.o.	P value
Clinical symptoms				
Dysphagia	-	-	-	-
Abdominal pain	-	1 (25%)	5 (100%)	0.001
GERD-like symptoms	2 (50%)	2 (50%)	-	0.08
Failure to thrive	1 (25%)	-	1 (25%)	0.4
Histopathology result				
Peak eosinophil count/ hpf	27.5 (IQR: 22.5–45)	60 (IQR: 50–80)	40 (IQR: 15–40)	0.1

IQR – interquartile range

Overall, 70% of the children ($n=33$) had a positive personal history of any allergic disease (asthma, rhinitis, food allergy, eczema). IgE was assessed in 29 patients (62%); in 59% of these patients it was elevated (greater than 2 SD of the median for the age). In 90% of patients, the peripheral eosinophils count was elevated (greater than 4% of white blood cells, median 7.3%; IQR: 4.8–9). Significantly more frequent hypersensitivity to aeroallergens was observed in children age 3 years or older ($p<0.05$) (Tab. 1).

To assess for the presence of celiac disease, all of the patients underwent duodenal mucosa biopsy, and 81% of patients underwent biopsy in conjunction with serology testing (anti-endomysial or anti-transglutaminase antibodies). On that basis, 4 of the 47 patients (9%) were diagnosed with comorbid celiac disease. Additionally, 9 patients (19%) were diagnosed with GERD using 24 hour pH-monitoring in the esophagus (Tab. 1).

DISCUSSION

In recent years, the increasing incidence and prevalence of eosinophilic esophagitis has led to EoE becoming one of the most prevalent oesophageal diseases and the leading cause of dysphagia and food impaction in children and young adults [5].

In the current study, the most common clinical symptom was abdominal pain, which affected more than half of the patients. On performing age-group analysis, it was found that GERD-like symptoms and failure to thrive were the most common symptoms in children ≤3 years, while abdominal pain and dysphagia were the most common symptoms in children older than 10 years. Dysphagia and food impaction are characteristic features of EoE in older children and adults. In this study, dysphagia occurred in 19% of all children. The results are in line with those of previous EoE studies in which dysphagia was observed in 4.8–60.9% of children and in 46.2–94.5% of adults [14].

In the presented cohort of patients, white exudates and furrows were the 2 most typical endoscopic findings. This result are similar to those of a recent review of endoscopic findings that analysed almost 2,000 children and adolescents with newly-diagnosed EoE [15]. In addition, one of the most important papers on EoE, a meta-analysis of more than 100 studies of both children and adults with EoE, (Kim et al.,

2012) reported that there were significant differences between children and adults. The authors found that oedema and exudates were more common in children, whereas rings and strictures were more common in adults [11]. These results might be attributed to the longer disease duration in adults, but they might also be due to different phenotypes of EoE. The different endoscopic features of EoE in children versus adults may explain the different symptom presentations, as mentioned above. In the current study, none of the patients with dysphagia (which is characteristic for adults) presented with a macroscopically normal oesophagus. However, statistically significant differences and correlations were observed between endoscopic features and clinical symptoms in children.

The endoscopic findings are very suggestive for a diagnosis of EoE. Interestingly, however, there is a group of patients that have no visually suggestive findings in the oesophagus. In this study, 27.6% of all the children had visually normal oesophageal mucosa at the time of EoE diagnosis. Bolton et al. found that between 10% – 33% of children with EoE presented with a macroscopically normal oesophagus [15]. In the current study, no differences were observed in this subgroup in terms of clinical symptoms, or in the density of eosinophilic infiltration. Therefore, it can be concluded that endoscopic findings alone do not reliably establish a diagnosis of EoE, or its severity. This finding also leads to the conclusion that oesophageal biopsies should be routinely obtained in all children referred for gastroscopy due to upper GI symptoms.

Other studies have shown the inconsistency between disease activity and microscopic findings (density of eosinophil infiltration) in children with EoE [16, 17, 18, 19]. The presented findings indicate that there are no correlations between the density of eosinophil infiltration (eosinophil peak count), the clinical manifestations and the endoscopic features ($p>0.05$). In adults, EoE activity is currently assessed using the validated Eosinophilic Activity Index (EeAI) and the Dysphagia Symptom Questionnaire; in children it is assessed using the Paediatric EoE Symptom Score (PEESS) [20, 21, 22, 23]. In addition to these tools, histopathological assessment continues to be necessary for monitoring disease activity. Further trials are required to establish optimal non-invasive methods for EoE activity evaluation to reduce the need for repeated endoscopies with biopsies. This is especially true for the paediatric population, which in most cases necessitates general anaesthesia to perform the procedure.

Despite the possibility of using different histopathological changes for EoE diagnosis, the diagnosis mainly relies on a peak count of 15 eosinophils per hpf. Recently, in addition to peak eosinophil count, an EoE-specific histological scoring system (EoEHSS) has been developed to provide a standardised method to evaluate oesophageal biopsies [24]. Unfortunately, EoEHSS is not commonly used by histopathologists, and it was not possible to apply it in the current study.

During the data collection process in this study, some recommendations on EoE were changed, one of which was regarding celiac disease and GERD comorbidities [4,5]. According to the latest guidelines, in this study, GERD and celiac disease were not applied as exclusion criteria of EoE. Moreover, comorbidity of those conditions were determined and it was found that GERD affected nearly one-fifth of the patients.

CONCLUSIONS

The results of this study indicate that in the paediatric population with newly-diagnosed EoE, the density of eosinophil infiltration does not correlate with the clinical symptoms or with the endoscopic findings. In patients with suspected EoE, multiple oesophageal biopsies are recommended, even if there are no macroscopic findings upon endoscopy.

REFERENCES

1. Navarro P, Arias Á, Arias-González L, Laserna-Mendieta EJ, Ruiz-Ponce M, Lucendo AJ. Systematic review with meta-analysis: the growing incidence and prevalence of eosinophilic oesophagitis in children and adults in population-based studies. *Aliment Pharmacol Ther.* 2019; 49: 1116–1125. <https://doi.org/10.1111/apt.15231>
2. Suryawala K, Palle S, Altaf MA. Epidemiology, Clinical Presentation, and Seasonal Variation in the Diagnosis of Children with Eosinophilic Esophagitis in Oklahoma. *South Med J.* 2020; 113: 37–41. <https://doi.org/10.14423/SMJ.0000000000001049>
3. Chehade M, Jones SM, Pesek RD, Burks AW, Vickery BP, Wood RA, et al. Phenotypic Characterization of Eosinophilic Esophagitis in a Large Multicenter Patient Population from the Consortium for Food Allergy Research. *J Allergy Clin Immunol Pract.* 2018; 6: 1534–1544. <https://doi.org/10.1016/j.jaip.2018.05.038>
4. Liacouras CA, Furuta GT, Hirano I, Atkins D, Attwood SE, Bonis PA, et al. Eosinophilic esophagitis: Updated consensus recommendations for children and adults. *J Allergy Clin Immunol.* 2011; 128: 1–20. <https://doi.org/10.1016/j.jaci.2011.02.040>
5. Lucendo AJ, Molina-Infante J, Arias Á, von Arnim U, Bredenoord AJ, Bussmann C, et al. Guidelines on eosinophilic esophagitis: evidence-based statements and recommendations for diagnosis and management in children and adults. *United European Gastroenterol J.* 2017; 5: 335–58. <https://doi.org/10.1177/2050640616689525>
6. Azzano P, Villard Truc F, Collardeau-Frachon S, Lachaux A. Children with eosinophilic esophagitis in real life: 10 years' experience with a focus on allergic management. *Allergol Immunopathol. (Madr).* 2020; 48: 244–250. <https://doi.org/10.1016/j.aller.2019.07.013>
7. Ancellin M, Ricolfi-Waligova L, Clerc-Urmès I, Schweitzer C, Maudinas R, Bonneton M, et al. Management of eosinophilic esophagitis in children according to atopic status: A retrospective cohort in northeast of France. *Arch Pediatr.* 2020; 27: 122–127. <https://doi.org/10.1016/j.arcped.2020.02.001>
8. Hirano I, Chan ES, Rank MA, Sharaf RN, Stollman NH, Stukus DR, et al. AGA institute and the joint task force on allergy-immunology practice parameters clinical guidelines for the management of eosinophilic esophagitis. *Ann Allergy Asthma Immunol.* 2020; 124: 416–423. <https://doi.org/10.1016/j.anai.2020.03.020>
9. Williamson P, Aceves S. Allergies and Eosinophilic Esophagitis-Current Updates for the Pediatric Gastroenterologist. *Curr Gastroenterol Rep.* 2019; 21: 56. <https://doi.org/10.1007/s11894-019-0729-y>
10. Gómez-Aldana A, Jaramillo-Santos M, Delgado A, Jaramillo C, Lúquez-Mindiola A. Eosinophilic esophagitis: Current concepts in diagnosis and treatment. *World J Gastroenterol.* 2019; 25: 4598–4613. <https://doi.org/10.3748/wjg.v25.i32.4598>
11. Kim HP, Vance RB, Shaheen NJ, Dellon ES. The prevalence and diagnostic utility of endoscopic features of eosinophilic esophagitis: a meta-analysis. *Clin Gastroenterol Hepatol.* 2012; 10: 988–96. <https://doi.org/10.1016/j.cgh.2012.04.019>
12. Hiremath G, Correa H, Acra S, Dellon ES. Correlation of endoscopic signs and mucosal alterations in children with eosinophilic esophagitis. *Gastrointest Endosc.* 2020; 91: 785–794. <https://doi.org/10.1016/j.gie.2019.11.031>
13. Hoofien A, Dias JA, Malamisura M, Rea F, Chong S, Oudshoorn J, et al. Pediatric eosinophilic esophagitis: Results of the European Retrospective Pediatric Eosinophilic Esophagitis Registry (RetroPEER). *J Pediatr Gastroenterol Nutr.* 2019; 68: 552–8. <https://doi.org/10.1097/MPG.0000000000002215>
14. Shaheen NJ, Mukkada V, Eichinger CS, Schofield H, Todorova L, Falk GW. Natural history of eosinophilic esophagitis: a systematic review of epidemiology and disease course. *Dis Esophagus.* 2018; 31: 8. <https://doi.org/10.1093/dote/doy015>
15. Bolton SM, Kagalwalla AF, Wechsler JB. Eosinophilic Esophagitis in Children: Endoscopic findings at diagnosis and post-intervention. *Curr Gastroenterol Rep.* 2018; 20: 4. <https://doi.org/10.1007/s11894-018-0607-z>
16. Collins MH, Martin LJ, Wen T, Abonia JP, Putnam PE, Mukkada VA, et al. Eosinophilic Esophagitis Histology Remission Score: Significant Relations to Measures of Disease Activity and Symptoms. *J Pediatr Gastroenterol Nutr.* 2020; 70: 598–603. <https://doi.org/10.1097/MPG.0000000000002637>
17. Gupta SK, Vitanza JM, Collins MH. Efficacy and safety of oral budesonide suspension in pediatric patients with eosinophilic esophagitis. *Clin Gastroenterol Hepatol.* 2015; 13: 66–76. <https://doi.org/10.1016/j.cgh.2014.05.021>
18. Schoepfer AM, Simko A, Bussmann C, Safroneeva E, Zwahlen M, Greuter T, et al. Eosinophilic Esophagitis: Relationship of Subepithelial Eosinophilic Inflammation With Epithelial Histology, Endoscopy, Blood Eosinophils, and Symptoms. *Am J Gastroenterol.* 2018; 113: 348–357. <https://doi.org/10.1038/ajg.2017.493>
19. Wechsler JB, Bolton SM, Amsden K, Wershil BK, Hirano I, Kagalwalla AF. Eosinophilic Esophagitis Reference Score Accurately Identifies Disease Activity and Treatment Effects in Children. *Clin Gastroenterol Hepatol.* 2018; 16: 1056–1063. <https://doi.org/10.1016/j.cgh.2017.12.019>
20. Schoepfer AM, Straumann A, Panczak R, Coslovsky M, Kuehni CE, Maurer E, et al. Development and validation of a symptom-based activity index for adults with eosinophilic esophagitis. *Gastroenterology* 2014; 147: 1255–66. <https://doi.org/10.1053/j.gastro.2014.08.028>
21. Dellon ES, Irani A-M, Hill MR, Hirano I. Development and field testing of a novel patient-reported outcome measure of dysphagia in patients with eosinophilic esophagitis. *Aliment Pharmacol Ther* 2013; 38: 634–42. <https://doi.org/10.1111/apt.12413>
22. Franciosi JP, Hommel KA, DeBrosse CW, Allison B, Greenberg AB, Greenler AJ, Abonia JP, et al. Development of a validated patient-reported symptom metric for pediatric eosinophilic esophagitis: qualitative methods. *BMC Gastroenterol.* 2011; 11: 126. <https://doi.org/10.1186/1471-230X-11-126>
23. Martin LJ, Franciosi JP, Collins MH, Abonia JP, Lee JJ, Hommel KA, et al. Pediatric Eosinophilic Esophagitis Symptom Scores (PEESS v2.0) identify histologic and molecular correlates of the key clinical features of disease. *J Allergy Clin Immunol* 2015; 135: 1519–28. <https://doi.org/10.1016/j.jaci.2015.03.004>
24. Collins MH, Martin LJ, Alexander ES, Boyd JT, Sheridan R, He H, et al. Newly developed and validated eosinophilic esophagitis histology scoring system and evidence that it outperforms peak eosinophil count for disease diagnosis and monitoring. *Dis Esophagus.* 2016; 30: 1–8. <https://doi.org/10.1111/dote.12470>